

ATS Core Curriculum 2021

Pediatric Pulmonary Medicine: Pulmonary Infections

Jane E. Gross¹, Michael Y. McCown², Caroline U. A. Okorie³, Lara C. Bishay⁴, Fei J. Dy⁵, Carmen Leon Astudillo⁶, Marianne S. Muhlebach⁷, Sara Abu-Nassar⁷, Diana Y. Chen³, Nazia Hossain³, Ruobing Wang⁸, Timothy Klouda⁸, Stacey L. Martiniano⁹, Patricia Lenhart-Pendergrass⁹, Stephen Kirkby¹⁰, Robin Ortenberg¹⁰, Jakob I. McSparron¹¹, Tisha Wang¹², Margaret M. Hayes¹³, and Başak Çoruh¹⁴

¹National Jewish Health, Denver, Colorado; ²Walter Reed National Military Medical Center, Bethesda, Maryland; ³Stanford University, Stanford, California; ⁴Children's Hospital of Los Angeles, Los Angeles, California; ⁵University of Massachusetts Medical School, University of Massachusetts, Worcester, Massachusetts; ⁶University of Florida, Gainesville, Florida; ⁷University of North Carolina at Chapel Hill, Chapel Hill, North Carolina; ⁸Boston Children's Hospital, Boston, Massachusetts; ⁹Children's Hospital Colorado, University of Colorado, Aurora, Colorado; ¹⁰Nationwide Children's Hospital, Columbus, Ohio; ¹¹University of Michigan, Ann Arbor, Michigan; ¹²University of California, Los Angeles, California; ¹³Beth Israel Deaconess Medical Center, Boston, Massachusetts; and ¹⁴University of Washington, Seattle, Washington

ABSTRACT

The following is a concise review of the Pediatric Pulmonary Medicine Core reviewing pediatric pulmonary infections, diagnostic assays, and imaging techniques presented at the 2021 American Thoracic Society Core Curriculum. Molecular methods have revolutionized microbiology. We highlight the need to collect appropriate samples for detection of specific pathogens or for panels and understand the limitations of the assays. Considerable progress has been made in imaging modalities for detecting pediatric pulmonary infections. Specifically, lung ultrasound and lung magnetic resonance imaging are promising radiation-free diagnostic tools, with results comparable with their radiation-exposing counterparts, for the evaluation and management of pulmonary infections. Clinicians caring for children with pulmonary disease should ensure that patients at risk for nontuberculous mycobacteria disease are identified and receive appropriate nontuberculous mycobacteria screening, monitoring, and treatment. Children with coronavirus disease (COVID-19) typically present with mild symptoms, but some may develop severe disease. Treatment is mainly supportive care, and most patients make a full recovery. Anticipatory guidance and appropriate counseling from pediatricians on social distancing and diagnostic testing remain vital to curbing the pandemic. The pediatric immunocompromised patient is at risk for invasive and opportunistic pulmonary infections. Prompt recognition of predisposing risk factors, combined with knowledge of clinical characteristics of microbial pathogens, can assist in the diagnosis and treatment of specific bacterial, viral, or fungal diseases.

Keywords:

molecular diagnostics; imaging; COVID-19; nontuberculous mycobacteria; immune compromise

(Received in original form March 8, 2021; accepted in final form May 25, 2021)

ATS Scholar Vol 2, Iss 3, pp 452–467, 2021

Copyright © 2021 by the American Thoracic Society

DOI: 10.34197/ats-scholar.2021-0034RE

DIAGNOSTIC ASSAYS

Marianne S. Muhlebach and Sara Abu-Nassar

A variety of organisms infect the airways and lung parenchyma, including bacteria, mycobacteria, viruses, and fungi. Diagnostic methods have improved greatly in recent years, yet culture remains the clinical gold standard for bacteria, mycobacteria, and fungi. Disadvantages of culture include a limited spectrum of culturable organisms, the time until results, and personnel efforts. Advantages include quantitative results and the ability to further test the organism. Besides conventional identification of organisms by growth characteristics and biochemical testing, 16S rRNA sequencing and mass spectrometry (matrix-assisted laser desorption ionization–time-of-flight mass spectrometry) have enhanced the sensitivity and accuracy of species-level identification.

Culture-independent methods typically rely on amplification of bacterial or viral nucleic acids and subsequent identification (1). Polymerase chain reaction (PCR) with or without quantitation has been available the longest, and newer, refined methods of nucleic acid extraction and amplification have streamlined the process, including isothermal nucleic acid extraction and amplification for high-throughput and point-of care testing. Several syndromic panels for upper and lower respiratory tract infections are commercially

available (2). These multiplex panels include bacterial, atypical bacterial, and viral co-detection, often with concomitant detection of bacterial resistance genes. Sensitivity and specificity vary among panels and specimen types. Sensitivity for different targets may differ within a sample, and detection of bacterial resistance in a mixed infection may not be pathogen specific (3). Increasingly, panels are semiquantitative to decrease uncertainty about contamination versus a clinically relevant bacterial load. Figure 1 demonstrates standard pathways for respiratory organism identification.

Clinicians should understand the appropriate specimen type (swab, induced or expectorated sputum, bronchoalveolar lavage fluid) relevant to the clinical question and recognize that sample quality and contamination are a few of the issues that may affect interpretation, especially for molecular diagnostics (4).

Viral Diagnostics

Viral detection is largely PCR-based, with many point-of-care methods for single or multiplex detection being available. Separate panels are optimized and Food and Drug Administration–approved for upper and lower respiratory tract samples. Antigen-based viral detection is widely used (e.g., influenza, severe acute respiratory syndrome coronavirus 2 [SARS-CoV-2]) and has rapid results but lower performance.

This article is open access and distributed under the terms of the Creative Commons Attribution Non-Commercial No Derivatives License 4.0. For commercial usage and reprints, please e-mail Diane Gern.

Author Contributions: The following authors conceived and provided a first draft of each of the following sections: DIAGNOSTIC ASSAYS (M.S.M. and S.A.-N.), NEW AND EVOLVING IMAGING MODALITIES (D.Y.C. and N.H.), NTM DIAGNOSIS AND MANAGEMENT (S.M. and P.L.-P.), PEDIATRIC COVID-19 (R.W. and T.K.), and INFECTIONS IN THE IMMUNOCOMPROMISED HOST (S.K. and R.O.). J.E.G., M.Y.M., and C.U.A.O. coordinated the team and prepared the manuscript draft with editing assistance from L.C.B., F.J.D., C.L.A., J.I.M., T.W., M.M.H., and B.Ç. All authors contributed to editing the final version to be published.

Correspondence and requests for reprints should be addressed to Jane E. Gross, M.D., Ph.D., National Jewish Health, 1400 Jackson Street, J329, Denver, CO 80206. E-mail: grossjane@njhealth.org.

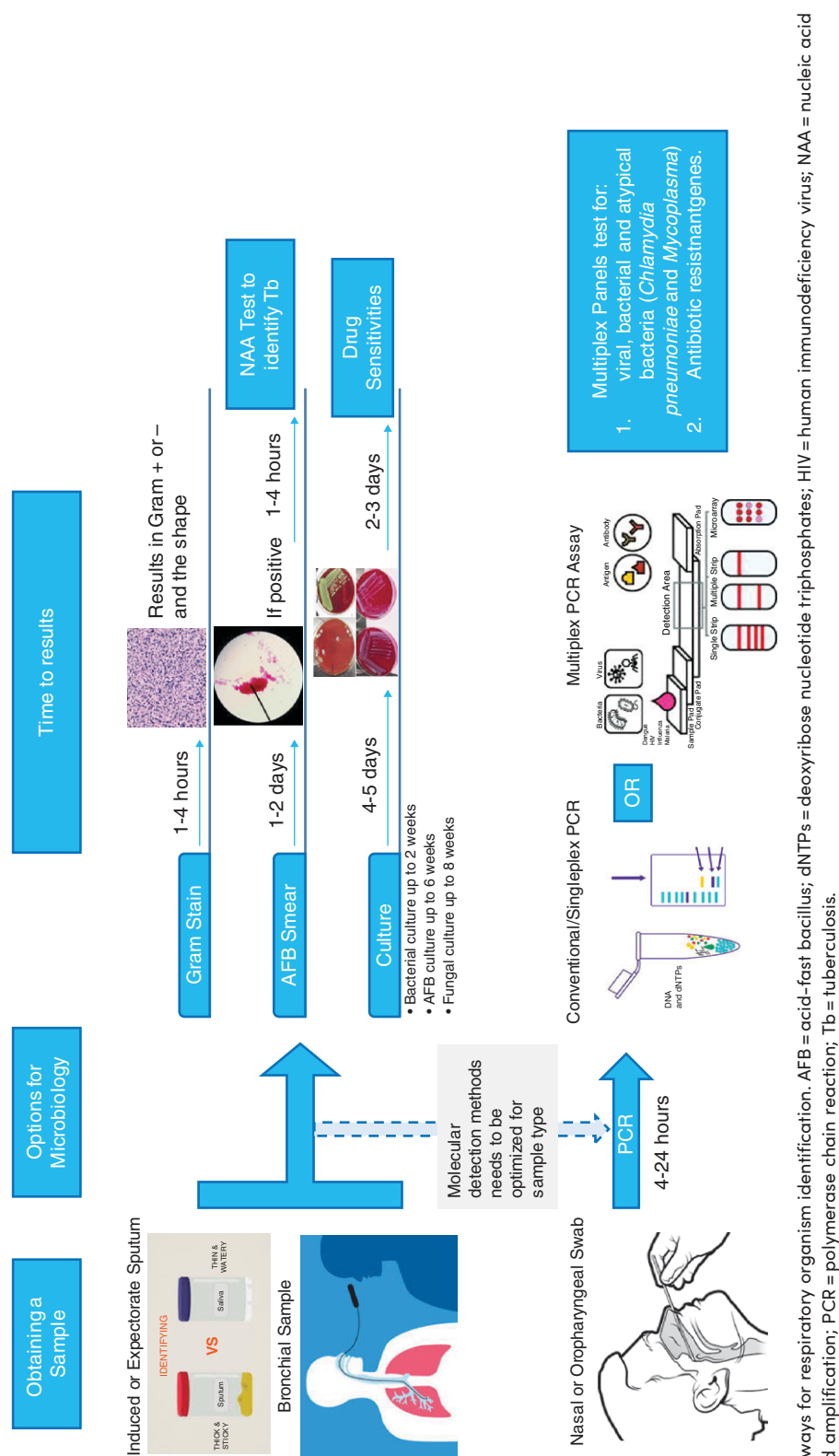


Figure 1. Pathways for respiratory organism identification. AFB = acid-fast bacillus; dNTPs = deoxyribose nucleotide triphosphates; HIV = human immunodeficiency virus; NAA = nucleic acid extraction and amplification; PCR = polymerase chain reaction; Tb = tuberculosis.

Fungal Diagnostics

Fungal diagnostics are often used in immunocompromised patients (ICPs). Culture and histopathology of secretions or tissues with fungus-specific staining remain valuable. Molecular methods include pan-fungal PCR and pathogen-specific PCR. Some syndromic lower respiratory infection panels include targets for *Aspergillus fumigatus*, *Pneumocystis jirovecii*, and *Cryptococcus neoformans* (5). To date, there are few published evaluations of those tests. Antigen detection assays are available for *Cryptococcus*, *Aspergillus* (galactomannan), *Candida* (enolase), and β -glycan as nonspecific markers of fungal infection. Given the concern of contamination from upper airway secretions, evaluation of the host's immune response to fungus can provide

specificity. Assays include complement-fixation, immunodiffusion, and enzyme immune assays.

Mycobacterial Diagnostics

Diagnosis of mycobacterial infections remains challenging, given the fastidious nature of the organisms. Culture remains the gold standard, followed by *Mycobacterium tuberculosis*-specific PCR (6). Skin and serologic tests are routinely used for tuberculosis, with cautious interpretation being used for ICPs. For nontuberculous mycobacteria (NTM), culture remains the standard in most settings; however, molecular assays and panmycobacterial PCR with gene sequencing for subtype identification are becoming available (7).

REFERENCES

1. Fukuda K, Ogawa M, Taniguchi H, Saito M. Molecular approaches to studying microbial communities: targeting the 16S ribosomal RNA gene. *J UOEH* 2016;38:223–232.
 2. Poole S, Clark TW. Rapid syndromic molecular testing in pneumonia: the current landscape and future potential. *J Infect* 2020;80:1–7.
 3. Collins ME, Popowitch EB, Miller MB. Evaluation of a novel multiplex PCR Panel compared to quantitative bacterial culture for diagnosis of lower respiratory tract infections. *J Clin Microbiol* 2020; 58:1–8.
 4. Hanson KE, Azar MM, Banerjee R, Chou A, Colgrove RC, Ginocchio CC, *et al.*; Diagnostics Committee of the Infectious Diseases Society of America (IDSA). Molecular testing for acute respiratory tract infections: clinical and diagnostic recommendations from the IDSA's Diagnostics Committee. *Clin Infect Dis* 2020;71:2744–2751.
 5. Kidd SE, Chen SC-A, Meyer W, Halliday CL. A new age in molecular diagnostics for invasive fungal disease: are we ready? *Front Microbiol* 2020;10:2903.
 6. Lewinsohn DM, Leonard MK, LoBue PA, Cohn DL, Daley CL, Desmond E, *et al.* Official American Thoracic Society/Infectious Diseases Society of America/Centers for Disease Control and prevention clinical practice guidelines: diagnosis of tuberculosis in adults and children. *Clin Infect Dis* 2017;64:e1–e33.
 7. Simon A, Onya O, Mazza-Stalder J, Nicod L, Gilbert G, Katia J. Added diagnostic value of 16S rRNA gene pan-mycobacterial PCR for nontuberculous mycobacterial infections: a 10-year retrospective study. *Eur J Clin Microbiol Infect Dis* 2019;38:1873–1881.
-

NEW AND EVOLVING IMAGING MODALITIES

Diana Y. Chen and Nazia Hossain

In addition to clinical assessment and microbial tests, imaging studies can aid in the diagnosis and management of pulmonary infections. Although plain chest radiography (CXR) is often the preferred initial modality, findings are often normal or nonspecific. Chest computed tomography (CT) remains the gold standard for characterization of pulmonary infections but increases the total-dose radiation exposure. Lung ultrasound (LUS) and lung magnetic resonance imaging (MRI) have gained attention as radiation-free alternatives for pulmonary imaging. Video 1 shows common radiologic findings for pulmonary infections from the imaging modalities described in this review.

LUS

Although the diagnosis of pneumonia is made in a clinical context, CXR studies are often obtained, although appreciable false-negative rates and wide inter- and intraobserver interpretation variability are reported. LUS is an advantageous alternative diagnostic modality that can detect the presence of consolidations, focal B-lines, pleural line abnormalities, and effusions with significantly better sensitivity than (95.5% vs. 86.8%) and specificity similar to (95.3% vs. 98.2%) CXR alone or in combination with clinical findings, and the use of LUS results in

less interpretation variability (1, 2). LUS is better for diagnosing and characterizing pleural effusions and identifying mediastinal lymphadenopathy in suspected pulmonary tuberculosis than CXR (3, 4).

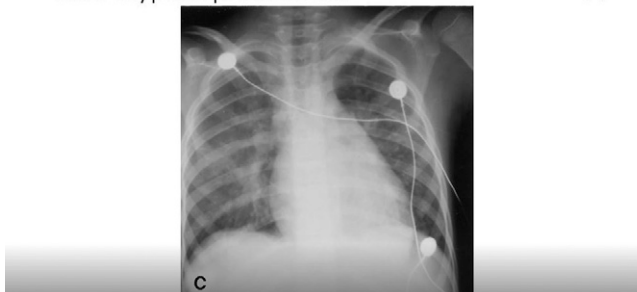
LUS techniques yield quality imaging results in children because of their unique anatomical features, including a thinner chest wall and smaller thoracic width. Advantages to LUS include the lack of radiation exposure, lower relative cost, potential for expanded access in low-resource settings, and rapid availability of results (5).

Chest CT versus MRI

CT is the gold standard for detecting pulmonary infection and for diagnosing bronchiectasis and air trapping. Despite routine use of pediatric low-dose CT protocols, minimizing the cumulative dose of radiation exposure in children remains crucial, particularly in patients with DNA-repairing deficiencies and oncologic conditions. With advances in imaging quality, emerging studies have aimed to validate MRI as a radiation-free alternative.

The advancements and development of MRI with fast-imaging sequences and higher field strengths have enhanced image resolution while reducing total scan times and the need for prolonged sedation (6). In detection of consolidations, cavitary lesions, nodules, ground-glass opacities (GGOs), pleural effusions, and lymph nodes, MRI has

CXR: atypical pneumonia



Video 1. Imaging in pulmonary infections.

demonstrated high sensitivity and specificity compared with CT (6, 7). Bronchiectasis scoring by using MRI correlates significantly with pulmonary exacerbations, respiratory symptoms, and the forced expiratory volume in 1 second in patients with cystic fibrosis (CF) (8). The availability of fast MRI sequences may vary among institutions because of the need for specific knowledge, training, and expertise. Lung MRI techniques continue to develop rapidly, and multicenter standardization trials are ongoing (9).

Coronavirus disease

Coronavirus disease (COVID-19), caused by SARS-CoV-2, has rapidly resulted in over

2.5 million deaths worldwide as of February 24, 2021. CT patterns of COVID-19 in adults are well described, with bilateral GGOs appearing in up to 88% of cases (10). In contrast, children with COVID-19 are three times more likely to have normal CT findings (35.7% of children vs. 8.4–10.2% of adults). CT manifestations are also less severe and show less bilateral involvement (27.7% of children vs. 73.8–78.8% of adults). GGO remains the most common feature (37.2%), followed by consolidations or infiltrates (22.3%). As GGOs are an atypical radiologic feature of other viral infections in children, detection can aid in early identification and risk stratification (11).

REFERENCES

1. Balk DS, Lee C, Schafer J, Welwarth J, Hardin J, Novack V, *et al.* Lung ultrasound compared to chest X-ray for diagnosis of pediatric pneumonia: a meta-analysis. *Pediatr Pulmonol* 2018;53:1130–1139.
2. Stadler JAM, Andronikou S, Zar HJ. Lung ultrasound for the diagnosis of community-acquired pneumonia in children. *Pediatr Radiol* 2017;47:1412–1419.
3. Pillay T, Andronikou S, Zar HJ. Chest imaging in paediatric pulmonary TB. *Paediatr Respir Rev* 2020;36:65–72.
4. Heuvelings CC, Bélard S, Andronikou S, Lederman H, Moodley H, Grobusch MP, *et al.* Chest ultrasound compared to chest X-ray for pediatric pulmonary tuberculosis. *Pediatr Pulmonol* 2019;54:1914–1920.
5. Copetti R, Cattarossi L. Ultrasound diagnosis of pneumonia in children. *Radiol Med (Torino)* 2008;113:190–198.
6. Sodhi KS, Khandelwal N, Saxena AK, Singh M, Agarwal R, Bhatia A, *et al.* Rapid lung MRI in children with pulmonary infections: time to change our diagnostic algorithms. *J Magn Reson Imaging* 2016;43:1196–1206.
7. Ozcan HN, Gormez A, Ozsurekci Y, Karakaya J, Oguz B, Unal S, *et al.* Magnetic resonance imaging of pulmonary infection in immunocompromised children: comparison with multidetector computed tomography. *Pediatr Radiol* 2017;47:146–153.
8. Tepper LA, Ciet P, Caudri D, Quittner AL, Utens EMWJ, Tiddens HAWM, *et al.* Validating chest MRI to detect and monitor cystic fibrosis lung disease in a pediatric cohort. *Pediatr Pulmonol* 2016;51:34–41.
9. Dournes G, Walkup LL, Benlala I, Willmering MM, Macey J, Bui S, *et al.* The clinical use of lung MRI in cystic fibrosis: what, now, how? *Chest* 2021;159:2205–2217.

10. Roshkovan L, Chatterjee N, Galperin-Aizenberg M, Gupta N, Shah R, Barbosa EM Jr, *et al.* The role of imaging in the management of suspected or known COVID-19 pneumonia: a multidisciplinary perspective. *Ann Am Thorac Soc* 2020;17:1358–1365.
11. Nino G, Zember J, Sanchez-Jacob R, Gutierrez MJ, Sharma K, Linguraru MG. Pediatric lung imaging features of COVID-19: a systematic review and meta-analysis. *Pediatr Pulmonol* 2021;56: 252–263.

NTM DIAGNOSIS AND MANAGEMENT

Stacey L. Martiniano and Patricia Lenhart-Pendergrass

NTM are ubiquitous in the environment, particularly in soil and water sources. They can cause uncommon, but significant, pulmonary disease in children (1, 2). These atypical pathogens are slow growing compared with typical bacteria and require special culture conditions for proper isolation and identification (3). NTM species associated with pulmonary disease in children include the *M. abscessus* group (MAB) (which includes the subspecies *abscessus*, *massiliense*, and *bolletii*), which typically grow within 1 week in culture, as well as slower growing species such as *M. avium* complex (MAC) (which includes *M. avium*, *M. intracellulare*, and *M. chimera*, among others) and *M. kansasii*, which can take weeks to grow in culture (4).

In the pediatric population, NTM infections most commonly occur in children with CF. Pulmonary NTM can also be diagnosed in children with non-CF bronchiectasis,

including primary ciliary dyskinesia, autosomal dominant hyper-IgE syndrome, and primary or secondary immunodeficiencies (5). MAC and MAB are the most common species associated with pulmonary disease in the United States.

Screening and Diagnosis

Annual screening for NTM should be performed in older children with CF via an expectorated or induced sputum culture, even if they are asymptomatic. Routine screening should also be considered in children with non-CF bronchiectasis. In addition, the presence of NTM should be considered in pulmonary infections or exacerbations that are unresponsive to treatment of typical pathogens or that present with an unexpected clinical decline. Because NTM can cause transient or indolent infection, or be a contaminant, it is imperative that careful consideration of the cause and a formal diagnosis of NTM pulmonary disease is made before starting treatment. Diagnostic criteria are shown in Figure 2. If a patient is on chronic

Clinical and Radiographic Criteria

1. Pulmonary or systemic symptoms, and
2. Nodular or cavitary opacities on chest radiograph, or a high-resolution computed tomography scan that shows bronchiectasis with small nodules, and
3. Appropriate exclusion of other diagnoses

Microbiologic Criteria

1. Positive culture from at least 2 separate expectorated sputum samples, or
2. Positive culture from at least one bronchial wash or lavage, or
3. Transbronchial or lung biopsy with mycobacterial histopathologic features (granulomatous inflammation or acid-fast bacilli) and positive culture for NTM from biopsy, sputum, or bronchial washing

Figure 2. Clinical and microbiologic criteria for diagnosis of nontuberculous mycobacteria pulmonary disease. Adapted from Reference 4.

Table 1. Treatment of typical nontuberculous mycobacteria infection (with consultation of an expert)

Organism	Antimicrobial Regimens
<i>M. avium</i> complex	<ul style="list-style-type: none"> • Oral azithromycin or clarithromycin, rifampin or rifabutin,* and ethambutol • For severe disease or if resistance is suspected, addition of IV or inhaled amikacin or clofazimine should be considered.
<i>M. abscessus</i> group	
Intensive phase	<ul style="list-style-type: none"> • IV amikacin plus IV imipenem, ceftazidime, or tigecycline • Oral azithromycin or clarithromycin* • 1 or 2 of the following: oral clofazimine, omadacycline, tedizolid, linezolid, bedaquiline, or moxifloxacin
Continuation phase	<ul style="list-style-type: none"> • Inhaled amikacin • Oral azithromycin or clarithromycin† • 1 or 2 of the following: oral clofazimine, omadacycline, tedizolid, linezolid, bedaquiline, or moxifloxacin
<i>M. kansasii</i>	Oral rifampin, isoniazid or macrolide, and ethambutol

Definition of abbreviations: IV = intravenous; *M.* = *Mycobacterium*.

Data are from References 4 and 6.

If a patient cannot receive rifampin because of a drug–drug interaction (e.g., ivacaftor), then an alternate antibiotic (e.g., clofazimine) should be used.

*Additional antimycobacterial agent needed if acquired or inducible resistance is present.

azithromycin therapy for immunomodulation, it should be stopped upon isolating NTM to avoid partial treatment and induced resistance.

Management

Management of NTM disease in children requires a prolonged course of multiple antibiotics, with the treatment choice being based on the species or subspecies and guided by susceptibilities. Expert consultation is recommended, especially for drug-resistant MAC or MAB (4). Standard treatment approaches are shown in Table 1 for the most common NTM (4, 6). Newer antibiotics that show *in vitro* activity against NTM are included on the basis of updated treatment

guidelines (6). Typically, MAC and *M. kansasii* can be treated with an oral antibiotic regimen. MAB requires an intensive phase of intravenous and oral antibiotics, which is followed by a continuation phase of oral and inhaled antibiotics. Daily treatment is recommended in children (vs. thrice-weekly treatment in adults) because of drug metabolism. Any patient started on NTM treatment requires frequent follow-up with intensive drug-toxicity monitoring (e.g., audiograms, vision testing, electrocardiography, and laboratory testing). The goal of treatment is to achieve 12 months of consecutive negative culture results. If microbiologic conversion cannot be achieved, drug concentrations should be measured and alternate antibiotics can be trialed.

REFERENCES

1. Feazel LM, Baumgartner LK, Peterson KL, Frank DN, Harris JK, Pace NR. Opportunistic pathogens enriched in showerhead biofilms. *Proc Natl Acad Sci USA* 2009;106:16393–16399.
 2. Martiniano SL, Nick JA, Daley CL. Nontuberculous mycobacterial infections in cystic fibrosis. *Clin Chest Med* 2016;37:83–96.
 3. Whittier S, Olivier K, Gilligan P, Knowles M, Della-Latta P; The Nontuberculous Mycobacteria in Cystic Fibrosis Study Group. Proficiency testing of clinical microbiology laboratories using modified decontamination procedures for detection of nontuberculous mycobacteria in sputum samples from cystic fibrosis patients. *J Clin Microbiol* 1997;35:2706–2708.
 4. Griffith DE, Aksamit T, Brown-Elliott BA, Catanzaro A, Daley C, Gordin F, *et al.*; ATS Mycobacterial Diseases Subcommittee; American Thoracic Society; Infectious Disease Society of America. An official ATS/IDSA statement: diagnosis, treatment, and prevention of nontuberculous mycobacterial diseases. *Am J Respir Crit Care Med* 2007;175:367–416. [Published erratum appears in *Am J Respir Crit Care Med* 175:744–745.]
 5. Bhattacharya J, Mohandas S, Goldman DL. Nontuberculous mycobacterial infections in children. *Pediatr Rev* 2019;40:179–190.
 6. Daley CL, Iaccarino JM, Lange C, Cambau E, Wallace RJ Jr, Andrejak C, *et al.* Treatment of nontuberculous mycobacterial pulmonary disease: an official ATS/ERS/ESCMID/IDSA clinical practice guideline. *Eur Respir J* 2020;56:2000535.
-

PEDIATRIC COVID-19

Ruobing Wang and Timothy Klouda

Since its identification in December 2019, SARS-CoV-2 has infected 20 million people in the United States, with an estimated 12% of cases occurring in children (1). The incidence of pediatric COVID-19 is likely underestimated because the majority of children with COVID-19 have mild or no symptoms, resulting in reduced disease screening and reporting. Despite children having better outcomes, they may contribute to transmission and are at risk for severe infection. Moreover, the pandemic has affected the lives of children because of disrupted education, decreased access to medical care, and increased mental health disorders (2).

Pathogenesis

The SARS-CoV-2 virus gains entry into cells by binding to the ACE2 receptor (3). The reason children experience less severe symptoms is unknown, and hypotheses include children having lower levels of ACE2, differential immune responses, and fewer comorbidities (4). To date, only age (less than 1 yr old) and having a preexisting medical condition have been identified as risk factors for severe disease in children (5).

Clinical Presentation

Children typically have mild symptoms and a fast recovery, with 17.4–19.3% of children with COVID-19 being asymptomatic (6, 7). The incubation period is estimated to be 2–14 days, and symptomatic patients typically recover in 2–4 weeks (8). Common symptoms include fever (51.2–59.1%), cough (37.0–55.9%), rhinorrhea (9.9–20.0%), and pharyngitis (8.3–18.2%) (6, 7).

Diagnostic Testing

Diagnosis of COVID-19 is typically through detection of viral mRNA from a respiratory

sample with reverse transcription–PCR. The accuracy of testing results depends on numerous factors, such as the sample source and the viral load present. Consultation with an infectious disease expert is recommended in certain clinical scenarios (e.g., congenital or acquired immunodeficiency) to ensure proper test interpretation and determine the need for possible retesting (8). Although laboratory findings have limited diagnostic and prognostic value, lymphopenia as well as elevated creatinine kinase, liver enzymes, and procalcitonin have been documented (7). CT abnormalities can present before clinical symptoms and may include GGOs and consolidations (6, 7).

Treatment and Management

Currently, there are no specific therapies for children with COVID-19. Stable patients are advised to quarantine at home (8). Treatment strategies for hospitalized patients include supplemental oxygen, fluid resuscitation, and empiric antibiotics when indicated (8). Systemic corticosteroids are not recommended. Patients in whom supplemental oxygen fails should be escalated to noninvasive positive pressure ventilation before mechanical ventilation with lung-protective strategies (9). Monoclonal antibodies to SARS-CoV-2 can be administered to high-risk pediatric patients 12 years or older who test positive for SARS-CoV-2 (10). To date, the Pfizer–BioNTech COVID-19 mRNA vaccine is the only vaccine available to patients 12 years or older. Clinical trials for patients under 12 years of age are currently ongoing.

Complications and Prognosis

An estimated 13.3% of pediatric patients with COVID-19 are admitted to the hospital, with 3.5% requiring intensive care unit (ICU) care. Mortality is low and is estimated to be less than 1% (5). Multisystemic inflammatory syndrome in children is a rare complication defined by fever, systemic inflammation, and

multiorgan dysfunction seen after COVID-19 infection in patients 3–12 years old. There are no established guidelines, and treatment includes intravenous immunoglobulin and glucocorticoids. With multisystemic inflammatory syndrome in children, 80% of patients require ICU care, and mortality is estimated at 2% (11).

REFERENCES

1. Demographic trends of COVID-19 cases and deaths in the US reported to CDC. Atlanta, GA: Centers for Disease Control and Prevention; 2020 [accessed 2020 Dec 27]. Available from: <https://covid.cdc.gov/covid-data-tracker/#datatracker-home>.
 2. Peck JL. COVID-19: impacts and implications for pediatric practice. *J Pediatr Health Care* 2020;34: 619–629.
 3. Zhou P, Yang XL, Wang XG, Hu B, Zhang L, Zhang W, *et al.* A pneumonia outbreak associated with a new coronavirus of probable bat origin. *Nature* 2020;579:270–273.
 4. Zimmermann P, Curtis N. Why is COVID-19 less severe in children? A review of the proposed mechanisms underlying the age-related difference in severity of SARS-CoV-2 infections. *Arch Dis Child* [online ahead of print] 2020 Dec 1; DOI: .
 5. Bellino S, Punzo O, Rota MC, Del Manso M, Urdiales AM, Andrianou X, *et al.*; COVID-19 WORKING GROUP. COVID-19 disease severity risk factors for pediatric patients in Italy. *Pediatrics* 2020;146:e2020009399.
 6. Hoang A, Chorath K, Moreira A, Evans M, Burmeister-Morton F, Burmeister F, *et al.* COVID-19 in 7780 pediatric patients: a systematic review. *EClinicalMedicine* 2020;24:100433.
 7. Ding Y, Yan H, Guo W. Clinical characteristics of children with COVID-19: a meta-analysis. *Front Pediatr* 2020;8:431.
 8. Chen ZM, Fu JF, Shu Q, Chen YH, Hua CZ, Li FB, *et al.* Diagnosis and treatment recommendations for pediatric respiratory infection caused by the 2019 novel coronavirus. *World J Pediatr* 2020;16:240–246.
 9. Terheggen U, Heiring C, Kjellberg M, Hegardt F, Kneyber M, Gente M, *et al.* European consensus recommendations for neonatal and paediatric retrievals of positive or suspected COVID-19 patients. *Pediatr Res* 2021;89:1094–1100.
 10. Cohen MS. Monoclonal antibodies to disrupt progression of early COVID-19 infection. *N Engl J Med* 2021;384:289–291.
 11. Feldstein LR, Rose EB, Horwitz SM, Collins JP, Newhams MM, Son MBF, *et al.*; Overcoming COVID-19 Investigators; CDC COVID-19 Response Team. Multisystem inflammatory syndrome in U.S. children and adolescents. *N Engl J Med* 2020;383:334–346.
-

INFECTIONS IN THE IMMUNOCOMPROMISED HOST

Stephen Kirkby and Robin Ortenberg

The pediatric ICP is at risk for invasive and opportunistic pulmonary infections. Prompt recognition of predisposing risk factors, combined with knowledge of clinical characteristics of microbial pathogens, can assist in the diagnosis and treatment of specific bacterial, viral, or fungal diseases.

Classification of Patients at Risk for Infection

There are hundreds of primary immunodeficiencies, further characterized by specific cellular defects (1). Disorders affecting T cells are likely to present with recurrent or severe viral and fungal infections. B-cell abnormalities lead to decreased antibody production and recurrent bacterial pneumonias, specifically caused by encapsulated organisms (2). Secondary immunodeficiencies vary in severity depending on the underlying cause of disease and include diabetes, malignancy, malnutrition, sickle-cell disease, human immunodeficiency virus, and immunomodulatory medication use. In addition, significant immunosuppressive states exist related to solid organ or bone marrow transplantation (3).

Diagnostic Evaluation

Evaluation of the ICP with respiratory symptoms should aim to quickly identify the source organism and rule out noninfectious etiologies. Imaging with CXR or CT can assist in identifying pathognomonic patterns of disease, in conjunction with specific laboratory studies. Bronchoscopy with bronchoalveolar lavage remains a key tool for diagnosis through cultures, cytology, and molecular diagnostic testing (such as PCR) (4). There may also be a limited role for lung biopsy (transbronchial or radiology-guided biopsy) or sampling of other tissues, such as

lymph nodes or skin (Table 2). Infectious disease consultants can offer valuable assistance in specific testing, particularly in complicated cases.

Bacterial Infections

Bacterial infections are commonly encountered among ICPs and may be acquired in the community or healthcare setting. Clinicians should have high clinical suspicion and quickly institute appropriate broad antibiotic coverage for gram-positive and gram-negative species, as the typical treatment for community-acquired pneumonia in immunocompetent hosts may be insufficient (5). Slow-growing bacterial species including mycobacteria and *Nocardia* species may also be identified in ICPs. Practitioners can tailor treatment to a specific pathogen once cultures and drug susceptibility patterns are identified.

Fungal infections

Although many fungi represent commensal or nonpathogenic organisms, others can cause true infection in the ICP. *P. jirovecii* is a common infection among organ transplant recipients as well as patients with chronic systemic glucocorticoid therapy or prolonged neutropenia or lymphopenia. Prophylactic strategies are often used in these high-risk patients. *Aspergillus* species, including *A. fumigatus*, may cause invasive pulmonary aspergillosis with sequelae such as necrotizing pneumonia, vascular invasion, and hematologic spread. These patients may present with hemoptysis or pulmonary infarction. The classic radiologic finding in invasive pulmonary aspergillosis is a cavitary lesion with surrounding GGO, the so-called “halo sign.” The highest-risk patients include those with hematologic malignancies and bone marrow transplant recipients. Other important fungal pathogens to consider in ICPs include mucormycosis, cryptococcosis, and *Candida*

Table 2. Characteristics of selected pulmonary infections in immunocompromised patients

Organism	Associated Immune Disorders and Risk Factors	Clinical Presentation	Characteristics of Diagnosis
<i>Aspergillus</i> species, specifically <i>A. fumigatus</i> (fungus)	• Neutropenia	• Fever	• Imaging: ground-glass opacities; cavitary nodules present with invasive disease
	• Hypo- or agammaglobulinemia	• Cough	• Serum testing: galactomannan; <i>Aspergillus</i> PCR
	• Immunosuppressive therapy	• Chest pain	• Bronchoscopy: tracheobronchitis with mucosal plaques and/or ulceration
	• BMT	• Throat pain	• BAL: fungal culture*; galactomannan: some studies show low sensitivity and possibility of cross-reactivity with other fungal infections; <i>Aspergillus</i> PCR: does not distinguish colonization from active infection
<i>C. neoformans</i> (fungus)		• Invasive pulmonary disease (severe presentation)	• Biopsy of nodule/tissue: septate hyphae with acute branching pattern
			• Elevated β -1,3-D-glucan in serum and/or BAL
			• Serum antigen testing
	• HIV	• Cough	• Imaging: diffuse interstitial findings; pulmonary nodules
	• Congenital T-cell disorders	• Fever	• BAL: India-ink stain reveals halo sign of polysaccharide capsule*; antigen testing
	• Immunosuppressive therapy	• Lymphadenopathy	• Low β -1,3-D-glucan in serum and/or BAL
		• Neurologic disease: headaches; meningismus	

Table 2. Continued.

Organism	Associated Immune Disorders and Risk Factors	Clinical Presentation	Characteristics of Diagnosis
<i>P. jirovecii</i> (fungus)	<ul style="list-style-type: none"> • Hypo- or agammaglobulinemia • Congenital T-cell disorders • HIV • Post-BMT • Immunosuppressive therapy • Neutropenia 	<ul style="list-style-type: none"> • Dyspnea • Fever • Cough • Cyanosis (late) • Hypoxemic respiratory failure (late) • Commonly presents with systemic findings due to hematogenous spread 	<ul style="list-style-type: none"> • Imaging: bilateral infiltrates; ground-glass or cystic lesions; nodules, with or without cavitation • BAL or sputum: direct identification of organism*; tinctorial staining; fluorescent antibody staining; PCR • Elevated β-1,3-D-glucan levels in serum and/or BAL
<i>Candida</i> species (fungus)	<ul style="list-style-type: none"> • Congenital T-cell disorders • Post-BMT • Chronic illness 	<ul style="list-style-type: none"> • White plaques on buccal mucosa 	<ul style="list-style-type: none"> • Imaging: microabscesses • Bronchoscopy: evidence of oropharyngeal plaques • Blood culture • BAL: Gram stain or potassium hydroxide preparation; budding yeasts with or without pseudohyphae • Elevated β-1,3-D-glucan (Fungitel) levels in serum and/or BAL
CMV (virus)	<ul style="list-style-type: none"> • Post-BMT • HIV • Neonates 	<ul style="list-style-type: none"> • Fever • Malaise • Cough 	<ul style="list-style-type: none"> • BAL: histopathology "owl-eye" inclusions or positive CMV-specific immunohistochemistry*; quantitative PCR; positive culture result • Serum: quantitative viral load; whole-blood PCR

Table 2. Continued.

Organism	Associated Immune Disorders and Risk Factors	Clinical Presentation	Characteristics of Diagnosis
<i>L. monocytogenes</i> (bacteria)	<ul style="list-style-type: none">• Neonates• HIV• Post-BMT status• Chronic gastrointestinal disease	<ul style="list-style-type: none">• Other organ symptoms: retinitis; encephalitis; colitis• Fevers• Chills• Can present initially with septicemia• Neurologic symptoms: meningismus; seizures; cranial nerve abnormalities; encephalitis	<ul style="list-style-type: none">• Radiology: ground-glass opacities• Serum and CSF: Gram stain and culture*; PCR*• BAL usually low-yield

Definition of abbreviations: *A. fumigatus* = *Aspergillus fumigatus*; BAL = bronchoalveolar lavage; BMT = bone marrow transplantation; *C. neoformans* = *Cryptococcus neoformans*; CMV = cytomegalovirus; CSF = cerebrospinal fluid; HIV = human immunodeficiency virus; *L. monocytogenes* = *Listeria monocytogenes*; *P. jirovecii* = *Pneumocystis jirovecii*; PCR = polymerase chain reaction.
*Gold standard.

infections. Published guidelines detail the diagnosis of pulmonary fungal infections (6).

Viral Infections

Seasonal community-acquired viral infections, including with influenza, respiratory syncytial virus, adenovirus, and other common upper respiratory tract viruses, are more likely to cause clinical pneumonia in pediatric ICPs. A high level of suspicion and prompt

diagnostic testing via PCR panels are indicated. Solid organ and bone marrow transplant recipients are at particularly high risk for cytomegalovirus, which can cause pneumonitis and other organ disease. Risk is based in part on the seropositivity of the donor and recipient, and prophylactic strategies are often employed (7).

Author disclosures are available with the text of this article at www.atsjournals.org.

REFERENCES

1. McCusker C, Upton J, Warrington R. Primary immunodeficiency. *Allergy Asthma Clin Immunol* 2018;14 (Suppl 2):61.
2. Jesenak M, Banovcin P, Jesenakova B, Babusikova E. Pulmonary manifestations of primary immunodeficiency disorders in children. *Front Pediatr* 2014;2:77.
3. Chinn IK, Orange JS. Immunodeficiency disorders. *Pediatr Rev* 2019;40:229–242.
4. Efrati O, Gonik U, Bielorai B, Modan-Moses D, Neumann Y, Szeinberg A, *et al*. Fiberoptic bronchoscopy and bronchoalveolar lavage for the evaluation of pulmonary disease in children with primary immunodeficiency and cancer. *Pediatr Blood Cancer* 2007;48:324–329.
5. Azoulay E, Russell L, Van de Louw A, Metaxa V, Bauer P, Povoia P, *et al*; Nine-i Investigators. Diagnosis of severe respiratory infections in immunocompromised patients. *Intensive Care Med* 2020;46: 298–314.
6. Hage CA, Carmona EM, Epelbaum O, Evans SE, Gabe LM, Haydour Q, *et al*. Microbiological laboratory testing in the diagnosis of fungal infections in pulmonary and critical care practice: an official American Thoracic Society clinical practice guideline. *Am J Respir Crit Care Med* 2019;200:535–550.
7. Pereyra F, Rubin RH. Prevention and treatment of cytomegalovirus infection in solid organ transplant recipients. *Curr Opin Infect Dis* 2004;17:357–361.