

## Syndromic congenital myelofibrosis associated with a loss-of-function variant in *RBSN*

Pilar L. Magoulas, M.S.<sup>1,2\*</sup>, Oleg A. Shchelochkov, M.D.<sup>3\*</sup>, Matthew N. Bainbridge, Ph.D.<sup>4</sup>, Shay Ben-Shachar, M.D.<sup>5</sup>, Svetlana Yatsenko, M.D.<sup>6,7,8</sup>, Lorraine Potocki, M.D.<sup>1,2</sup>, Richard Alan Lewis, M.D.<sup>2,9</sup>, Charles Searby, B.S.<sup>10</sup>, Andrea N. Marcogliese, M.D.<sup>1,11,12</sup>, M. Tarek Elghetany, M.D.<sup>1,11,12</sup>, Gladys Zapata<sup>2,13</sup>, Paula Patricia Hernández<sup>2,13</sup>, Manasi Gadkari, M.S.<sup>14</sup>, Derek Einhaus, B.S.<sup>14</sup>, Donna M. Muzny, M.S.<sup>15</sup>, Richard A. Gibbs, Ph.D.<sup>15</sup>, Alison A. Bertuch, M.D., Ph.D.<sup>1,12</sup>, Daryl A. Scott, M.D., Ph.D.<sup>1,2,16</sup>, Silvia Corvera, M.D.<sup>17</sup>, Luis M. Franco, M.D.<sup>14</sup>

<sup>1</sup> Texas Children's Hospital, Houston, Texas, USA

<sup>2</sup> Department of Molecular and Human Genetics, Baylor College of Medicine, Houston, Texas, USA

<sup>3</sup> Medical Genomics and Metabolic Genetics Branch, National Human Genome Research Institute, National Institutes of Health, Bethesda, Maryland, USA

<sup>4</sup> Codified Genomics; Institute for Genomic Medicine, Rady Children's Hospital, San Diego, California, USA

<sup>5</sup> Genetics Institute, Tel-Aviv Sourasky Medical Center, affiliated to Sackler Faculty of Medicine, Tel Aviv University, Tel Aviv, Israel

<sup>6</sup> Department of Obstetrics, Gynecology, and Reproductive Sciences, School of Medicine, University of Pittsburgh, Pittsburgh, Pennsylvania, USA

<sup>7</sup> Department of Pathology, School of Medicine, University of Pittsburgh, Pittsburgh, Pennsylvania, USA

<sup>8</sup> Department of Human Genetics, Graduate School of Public Health, University of Pittsburgh, Pittsburgh, Pennsylvania, USA

<sup>9</sup> Department of Ophthalmology, Baylor College of Medicine, Houston, Texas, USA

<sup>10</sup> University of Iowa, Iowa City, Iowa, USA

<sup>11</sup> Department of Pathology and Immunology, Baylor College of Medicine, Houston, Texas, USA

<sup>12</sup> Department of Pediatrics, Section of Hematology and Oncology, Baylor College of Medicine, Houston, Texas, USA

<sup>13</sup> USDA/ARS Children's Nutrition Research Center, Section of Nutrition, Department of Pediatrics, Baylor College of Medicine, Houston, Texas, USA

<sup>14</sup> Laboratory of Immune System Biology, National Institute of Allergy and Infectious Diseases, National Institutes of Health, Bethesda, Maryland, USA

<sup>15</sup> The Human Genome Sequencing Center, Baylor College of Medicine, Houston, Texas, USA

<sup>16</sup> Department of Molecular Physiology and Biophysics, Baylor College of Medicine, Houston, Texas, USA

<sup>17</sup> Program in Molecular Medicine, University of Massachusetts Medical School, Worcester, Massachusetts, USA

\* These authors contributed equally to this manuscript

Corresponding Author:

Luis M. Franco, M.D.

Assistant Clinical Investigator

Laboratory of Immune System Biology, DIR/NIAID

National Institutes of Health

9000 Rockville Pike

Building 4, Room 138

Bethesda, MD 20892

Phone: 301-761-5292

E-mail: luis.franco@nih.gov

To the editor:

The human proteins rabenosyn-5 and VPS45 form a complex that plays a key role in early endocytosis<sup>1-4</sup>. Pathogenic variants in *VPS45* cause severe congenital neutropenia (SCN) with impaired neutrophil function, reticulin fibrosis of the bone marrow, and extramedullary hematopoiesis (OMIM: 615285)<sup>5-8</sup>. Patients with a specific *VPS45* variant (p.Glu238Lys) also have intellectual disability and bilateral optic nerve hypoplasia<sup>5,6</sup>. To date, the only evidence of a potential role for *RBSN* in human disease is the report of a homozygous missense variant (p.Gly425Arg) in a patient with intellectual disability, seizures, microcephaly, osteopenia, mild reticulin fibrosis of the bone marrow, and transient neutropenia<sup>9</sup>.

We evaluated three siblings, born to consanguineous parents, for a phenotype of SCN, anemia, thrombocytopenia, reticulin fibrosis of the bone marrow, dysmorphic facial features, osteopenia, hypertriglyceridemia, hepatomegaly, microphthalmia, and optic nerve hypoplasia (Figure 1 A-E). Bone marrow examination revealed trilineage hematopoiesis without maturation arrest (Figure S1). Myelofibrosis was documented as early as 4 weeks of age and was progressive and severe (Figures S1 and S2). The proband (patient VI.2) had complete 46,XY male-to-female sex reversal and died at age 20 months after multiple infections. At autopsy, she was found to have extensive extramedullary hematopoiesis. The other two affected siblings (patients VI.3, and VI.4) are currently ages 9 and 5 years. They underwent unrelated-donor bone marrow or stem cell transplantation at 8 and 6.5 months of age, respectively. Post-transplantation bone marrow examinations have shown a reduction in myelofibrosis (Figure 1F) and their circulating blood counts have remained normal (Figure S3). Both have severe intellectual disability, are non-ambulatory and non-verbal. The clinical presentation is detailed in Table 1, Figures S1-S3, and Table S1.

The parents and a fourth sibling (patient VI.5), who is currently seven months of age, have no neurologic or ophthalmologic abnormalities. The fourth sibling had transient neonatal thrombocytopenia and anemia, and has persistent, mild neutropenia (Figure S4). The mother has had chronic moderate thrombocytopenia, an elevated immature platelet fraction, and peripheral blood smear with macrothrombocytes among variably-sized platelets. These findings have been interpreted as consistent with immune thrombocytopenia. Her CBC is otherwise normal. The father's CBC is normal.

Whole-exome sequencing on the proband (patient VI.2) revealed a variant (NM\_022340.3:c.289G>C; NP\_001289307.1:p.Gly97Arg) in *RBSN*, the gene encoding rabenosyn-5, which was homozygous in the three affected children, heterozygous in each parent and patient VI.5, and predicted to affect mRNA splicing and protein function (Figures S5 and S6A).

To assess splicing, we sequenced cDNA libraries from the proband (patient VI.2) and the father. Normally-spliced transcripts were not observed in the proband and represented 45% of transcripts in the father. The most common abnormal transcripts had skipping of exon 5 or an alternative exon 5a (Figure S7). High-throughput RNA sequencing confirmed these observations and revealed abnormally spliced transcripts that retain exon 5 and its neighboring introns (Figure S6B).

Immunoblotting showed an absence of intact rabenosyn-5 in the affected patients (Figure S6C).

Immunofluorescence staining revealed larger, clustered EEA1-positive endosomes in patient fibroblasts compared to controls (Figure S6D). These findings suggest that the absence of intact rabenosyn-5 affects the structure and function of early endosomes.

Transferrin uptake and recycling assays revealed quantitative and qualitative differences in cells from the affected patients compared to those from a healthy control. After 30 minutes of uptake, transferrin was localized to a more clustered perinuclear region in cells from the affected patient (Figure S6E). In addition, total transferrin accumulation was higher, and the washout phase was delayed, in cells from the affected patient (Figure S6F). These findings are consistent with a decreased rate of recycling of the transferrin receptor and increased steady-state intracellular accumulation of the ligand in cells harboring the *RBSN* variant. The perinuclear clustering and the increased transferrin accumulation were reversed in cells transfected with a version of the human *RBSN* gene that does not have the variant (Figure S8).

Our observations suggest that *RBSN* loss of function causes a severe syndromic form of congenital myelofibrosis, and they confirm that rabenosyn-5 plays a vital role in human development and hematopoiesis. The mechanisms by which *RBSN* loss of function leads to hematologic and developmental abnormalities are unknown. As previously suggested for *VPS45*, the neutropenia may result from apoptosis induced by the toxic effects of impaired endosomal trafficking<sup>5,7</sup>. It is important to note, however, that other congenital disorders associated with increased neutrophil apoptosis, such as pathogenic variants in *ELANE*, do not also result in congenital myelofibrosis. Thus, additional factors must be at play. One hypothesis is that the myelofibrosis results from impaired trafficking of  $\alpha$ -granules and their release from megakaryocytes, resulting in a pro-inflammatory, profibrotic response. Also, given that *RBSN* loss of function is predicted to result in a reduction of  $\beta 1$  integrin expression at the cell surface, as observed for *VPS45* deficiency<sup>5</sup>, it is tempting to speculate that the optic pathway and other central nervous system effects are the result of abnormal axonal transport of integrin transmembrane proteins during development.

The phenotypic overlap between our patients and those with mutation affecting *VPS45*<sup>5-8</sup> suggests the existence of a distinct disorder of early endocytosis caused by pathogenic variants in the genes encoding either member of the rabenosyn-5/VPS45 complex. SCN without maturation arrest, reticulin fibrosis of the bone marrow, and extramedullary hematopoiesis appear to be the hallmarks of the disease. Anemia and thrombocytopenia in our patients were variable and exacerbated by infection and progressive hepatosplenomegaly (Table S1 and Figure S3). Long-term survival without substantial hematologic or infectious complications was possible after bone marrow or stem cell transplantation, suggesting the hematopoietic defect is intrinsic to hematopoietic stem and progenitor cells, although a transferable factor from the transplanted cells to the bone marrow cannot be excluded. The neurologic and ophthalmologic abnormalities in the surviving patients have remained stable. Other concordant features in our patients include facial dysmorphism, abnormal bone development, and hypertriglyceridemia. The only sibling homozygous for the *RBSN* variant who had a 46,XY chromosome complement also had a disorder of sex development. This appears to be part of the syndrome, and we hypothesize that it could be the result of ineffective endocytosis of sex hormones *in utero*, as has been observed in animal models<sup>10</sup>. Confirmation will require additional cases of 46,XY individuals with loss-of-function *RBSN* variants.

The mother's hematologic abnormality is consistent with immune thrombocytopenia. This could explain the transient neonatal thrombocytopenia in the heterozygous sibling (patient VI.5), but it would not explain his transient anemia and persistent, mild neutropenia. It is certainly possible that the hematologic manifestations in these two individuals represent a milder phenotype caused by the *RBSN* variant in heterozygous state.

The structural and phenotypic effects of the variant we report are considerably more severe than those of the previously reported *RBSN* variant (p.Gly425Arg)<sup>9</sup>. In that patient, intact rabenosyn-5 was detected by immunoblot, the sub-cellular localization of the protein by immunofluorescence staining was normal, and transferrin endocytosis and recycling assays showed a significantly enhanced rate of recycling suggestive of a gain-of-function effect. However, the phenotypic overlap with our patients suggests that the p.Gly425Arg variant is also pathogenic, leading to a milder phenotype within the same spectrum. Therefore, pathogenic *RBSN* variants, in homozygous or heterozygous state, should also be considered in cases of unexplained transient neutropenia, particularly when neurologic abnormalities and/or myelofibrosis are also present.

### **Acknowledgements**

We thank the family who participated in the study and the healthcare providers who referred them to us for evaluation. We also thank Dr. Cynthia Dunbar for critical review of the manuscript. LMF is supported by the Intramural Research Program of the National Institute of Allergy and Infectious Diseases (NIAID) at the National Institutes of Health (NIH). OAS is supported by the Intramural Research Program of the National Human Genome Research Institute at the National Institutes of Health.

This study was approved by the Institutional Review Board for Human Subject Research at Baylor College of Medicine. The parents gave written informed consent before evaluation, counseling, and testing.

### **Explanation of Author Contributions:**

Designed and performed research: Shchelochkov, Bainbridge, Yatsenko, Searby, Zapata, Hernandez, Gadkari, Einhaus, Muzny, Gibbs, Bertuch, Corvera, Franco

Collected data: Magoulas, Shchelochkov, Ben-Shachar, Potocki, Lewis, Bertuch, Scott, Franco

Analyzed and interpreted data: Magoulas, Shchelochkov, Bainbridge, Yatsenko, Lewis, Searby, Marcogliese, Elghetany, Zapata, Hernandez, Gadkari, Einhaus, Muzny, Gibbs, Bertuch, Scott, Corvera, Franco

Performed statistical analysis: Corvera

Wrote the manuscript: Magoulas, Shchelochkov, Lewis, Bertuch, Scott, Corvera, Franco

Mrs. Magoulas, Dr. Shchelochkov, and Dr. Franco had full access to all the data in the study and take responsibility for the integrity of the data and the accuracy of the data analysis.

Mrs. Magoulas and Dr. Shchelochkov contributed equally to this study.

**Conflict of Interest Disclosure:** The authors report no conflicts of interest related to this work.

## References

1. Nielsen E, Christoforidis S, Uttenweiler-Joseph S, et al. Rabenosyn-5, a novel Rab5 effector, is complexed with hVPS45 and recruited to endosomes through a FYVE finger domain. *J Cell Biol.* 2000;151(3):601-612.
2. Naslavsky N, Boehm M, Backlund PS, Jr., Caplan S. Rabenosyn-5 and EHD1 interact and sequentially regulate protein recycling to the plasma membrane. *Mol Biol Cell.* 2004;15(5):2410-2422.
3. Navaroli DM, Bellve KD, Standley C, et al. Rabenosyn-5 defines the fate of the transferrin receptor following clathrin-mediated endocytosis. *Proc Natl Acad Sci U S A.* 2012;109(8):E471-480.
4. Tanaka T, Nakamura A. The endocytic pathway acts downstream of Oskar in Drosophila germ plasm assembly. *Development.* 2008;135(6):1107-1117.
5. Vilboux T, Lev A, Malicdan MC, et al. A congenital neutrophil defect syndrome associated with mutations in VPS45. *N Engl J Med.* 2013;369(1):54-65.
6. Meerschaut I, Bordon V, Dhooge C, et al. Severe congenital neutropenia with neurological impairment due to a homozygous VPS45 p.E238K mutation: A case report suggesting a genotype-phenotype correlation. *Am J Med Genet A.* 2015;167A(12):3214-3218.
7. Stepensky P, Saada A, Cowan M, et al. The Thr224Asn mutation in the VPS45 gene is associated with the congenital neutropenia and primary myelofibrosis of infancy. *Blood.* 2013;121(25):5078-5087.
8. Shah RK, Munson M, Wierenga KJ, Pokala HR, Newburger PE, Crawford D. A novel homozygous VPS45 p.P468L mutation leading to severe congenital neutropenia with myelofibrosis. *Pediatr Blood Cancer.* 2017;64(9).
9. Stockler S, Corvera S, Lambright D, et al. Single point mutation in Rabenosyn-5 in a female with intractable seizures and evidence of defective endocytotic trafficking. *Orphanet J Rare Dis.* 2014;9:141.



10. Hammes A, Andreassen TK, Spoelgen R, et al. Role of endocytosis in cellular uptake of sex steroids. *Cell*. 2005;122(5):751-762.

## Figure Legend

**Figure 1.** Family pedigree and phenotypic features of the patients.

A, Family pedigree indicating consanguinity. Filled symbols represent affected individuals (patients VI.2, VI.3, VI.4).

B, Photographs of patient VI.2 at 11 months, patient VI.3 at 9 years 2 months, and patient VI.4 at 4 years 11 months. Note microphthalmia, beaked nose, and prominent columella. Consent for the publication of images was provided by the patients' parents.

C, Absolute neutrophil count over time for the three patients. Shaded blue represents the normal reference range based on age. The upper limit of normal in the newborn period in our laboratory is  $23.5 \times 100/\mu\text{L}$ , which is above the range depicted (\*). HSCT: Hematopoietic stem cell transplantation. BMT: Bone marrow transplantation. DOD: Date of death.

D, Brain MRI of patient VI.3 at 9 months of age. Note supratentorial volume loss involving the white greater than the gray matter, ex vacuo ventricular enlargement, and optic nerve hypoplasia.

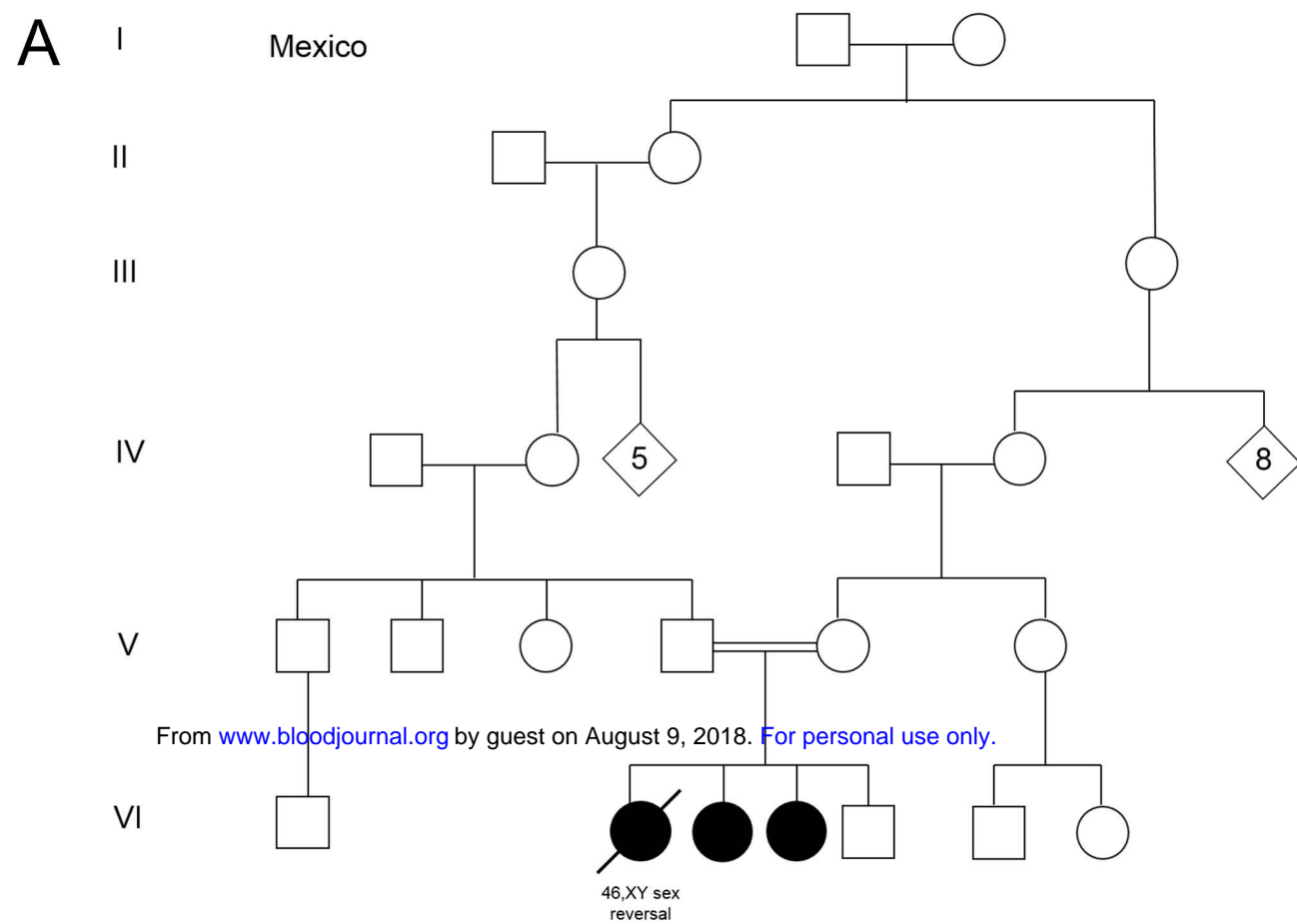
E, Bone marrow biopsy for patient VI.3 at 33 days of age. Reticulin stain, 200x magnification. Note moderate to severe reticulin fibrosis. Trichrome staining for collagen fibers was not performed.

F, Bone marrow biopsy for patient VI.3 at 20 months of age, one year after bone marrow transplantation. Reticulin stain, 200x magnification. Note the reduction in reticulin fibrosis to mild and focal. Trichrome staining for collagen fibers was negative (data not shown).

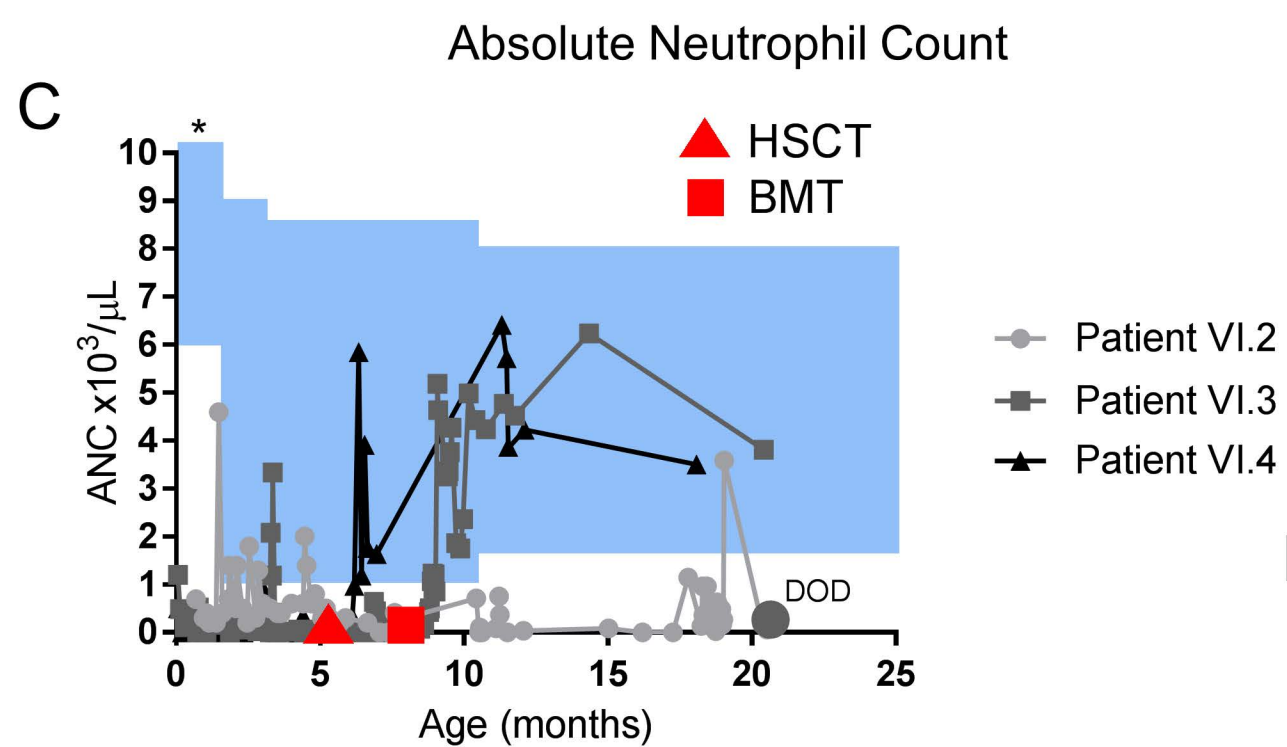
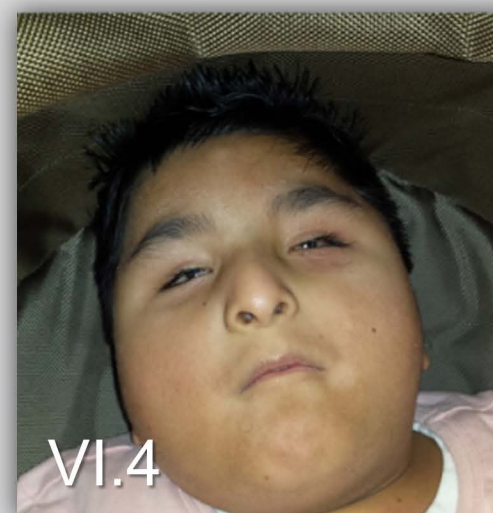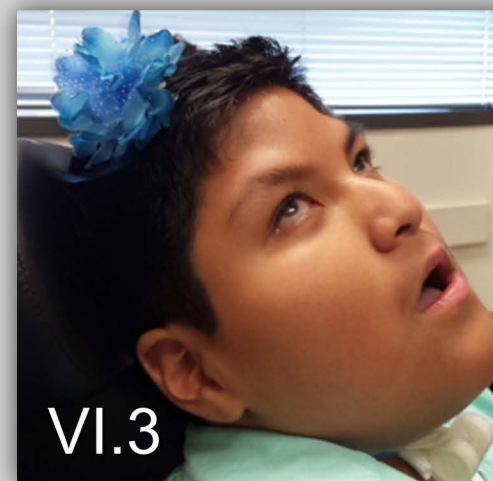
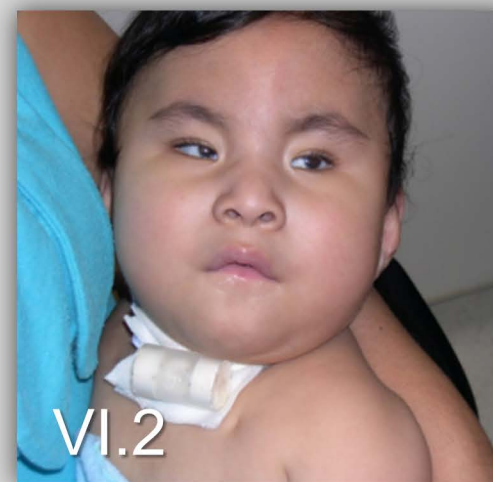**Table 1. Clinical, imaging, and histopathologic findings in three patients with a pathogenic *RBSN* variant**

	Patient VI.2	Patient VI.3	Patient VI.4
<b>Phenotype</b>	Female	Female	Female
<b>Chromosomes</b>	46,XY	46,XX	46,XX
<b>CMA</b>	Normal (BG v.5 and 400,000 oligonucleotide research array)	Normal (BG v.6.4)	Normal (BG v.8.3)
<b>Growth</b>	11 m: Ht: 25%; Wt: 75%; OFC: 25-50%	9 y 2 m: Ht: <1%, Wt: 76%, OFC: 18%	4 y 11 m: Ht: <1%, Wt: 57%, OFC: 5%
<b>Facial features</b>	Narrow bi-temporal diameter, metopic prominence, sloping forehead, upslanting palpebral fissures, epicanthal folds, bulbous nose, depressed nasal tip	Prominent nasal bridge, low set, posteriorly rotated ears, retromicrognathia, high-arched palate	Bitemporal narrowing, tubular nose, prominent columella
<b>Hematologic</b>	SCN transiently responsive to intermediate-dose filgrastim, PB NRBCs, progressive anemia and thrombocytopenia, hypercellular bone marrow with severe reticulin fibrosis and myeloid hyperplasia, extramedullary hematopoiesis (liver, spleen, kidneys, lymph nodes) on PME	SCN without maturation arrest, refractory to filgrastim, transfusion-dependent anemia, variable thrombocytopenia including at birth and with infection, PB NRBCs, normocellular bone marrow with moderate to severe reticulin fibrosis and maturing trilineage hematopoiesis	SCN refractory to filgrastim, moderate anemia at birth (variably present subsequently), PB NRBCs, hypercellular bone marrow with moderate to severe reticulin fibrosis and maturing trilineage hematopoiesis
<b>Ophthalmologic</b>	Poor visual response, microphthalmia, hypoplastic irides, microcornea, blepharophimosis, absent retinal vessels, aplastic optic nerves	Poor visual response, microphthalmia, microcornea, blepharophimosis, aplastic optic nerves	Poor visual response, microphthalmia, aniridia with iris coloboma, blepharophimosis, dysplastic optic nerves, absent retinal vessels
<b>Neurologic</b>	Increased muscle tone in the lower extremities, DTRs 2+, poor head control	Increased muscle tone in the four extremities, DTRs 3+, normal EEG	Joint restriction, hypotonia, diminished strength, muscle atrophy, normal DTRs
<b>Brain MRI</b>	Prominent supratentorial ventricles, sulci, and cisterns, widened sylvian fissures, thin corpus callosum, cerebral atrophy, severe optic nerve and chiasm hypoplasia, diffuse expansion of diploic calvarial marrow space	Perinatal intraparenchymal and subarachnoid hemorrhages. Supratentorial volume loss, thin corpus callosum, mild myelin maturation delay. Hypoplasia of the optic nerve, chiasm, and optic tract. Bone enhancement likely related to myelofibrosis	N/A
<b>Respiratory</b>	Tracheomalacia	Tracheomalacia	Normal
<b>Cardiovascular</b>	Mild cardiomegaly on PME	Small PDA, redundant atrial septum	Small PFO, small secundum ASD
<b>Gastrointestinal</b>	Gastrostomy feeding only, GE reflux, hepatosplenomegaly with extramedullary hematopoiesis on PME. Accessory spleen	Gastrostomy feeding only, mild esophageal dysmotility, hepatomegaly likely related to extramedullary hematopoiesis	Gastrostomy feeding only, hepatomegaly likely related to extramedullary hematopoiesis
<b>Orthopedic</b>	Osteopenia, congenital hip dysplasia. Tapered 5 <sup>th</sup> finger	Osteopenia, femur fracture, bilateral hip dysplasia, clinodactyly, delayed bone age (2-3 y), advanced bone age (6-7 y)	Delayed bone age (-3 SD below mean), bilateral hip dysplasia
<b>Genitourinary</b>	Hypoplastic labia minora and majora, underdeveloped genital tubercle, anteriorly placed anus. Streak gonads, uterine didelphys, and double vagina on PME. Nephromegaly with extramedullary hematopoiesis on PME	Nephromegaly, likely related to extramedullary hematopoiesis	Normal
<b>Endocrine</b>	Mild adrenal cortical lipid depletion and pituitary hypoplasia on PME, elevated FSH and LH for age, normal testosterone	Elevated FSH for age.	Normal
<b>Audiological</b>	Bilateral mild to moderate high-frequency sensorineural hearing impairment	Normal	N/A
<b>Immunologic</b>	Frequent infections ( <i>Pseudomonas aeruginosa</i> , <i>Stenotrophomonas maltophilia</i> , <i>Candida albicans</i> , influenza A virus, respiratory syncytial virus)	Normal Ig G, A, M, and E. Normal CH <sub>50</sub> activity. Normal numbers and ratios of CD4+ and CD8+ T cells and CD19+ B cells. NK cells and CD4+/CD45RA+ naïve T cells increased in absolute number, normal ratio. CD4+/CD45RO+ memory cells low in absolute number and ratio	Frequent urinary tract infections
<b>Metabolic</b>	Hypertriglyceridemia (249-335 mg/dL)	Hypertriglyceridemia (155-1086 mg/dL)	Hypertriglyceridemia (176-296 mg/dL)
<b>Development/Cognition</b>	Global developmental delay	9 y: Severe intellectual disability, non-verbal, non-ambulatory	5 y: Severe intellectual disability, non-verbal, non-ambulatory

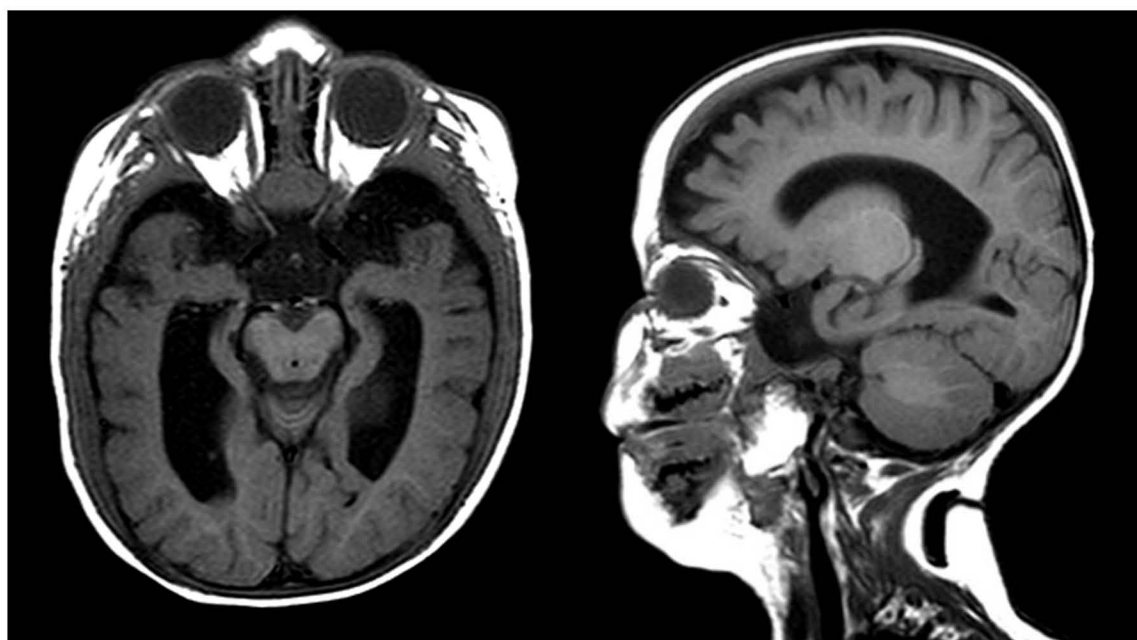CMA: Chromosomal microarray analysis. BG: Baylor Genetics Laboratory. SCN: Severe congenital neutropenia. PB NRBCs: Peripheral blood nucleated red blood cells. N/A: Not assessed. m: Months of age. y: Years of age. Ht: Height. Wt: Weight. OFC: Occipital frontal circumference. DTRs: Deep tendon reflexes. EEG: Electroencephalogram. PME: Postmortem examination. PDA: Patent ductus arteriosus. PFO: Patent foramen ovale. ASD: Atrial septal defect; GE: Gastroesophageal. SD: Standard deviations.



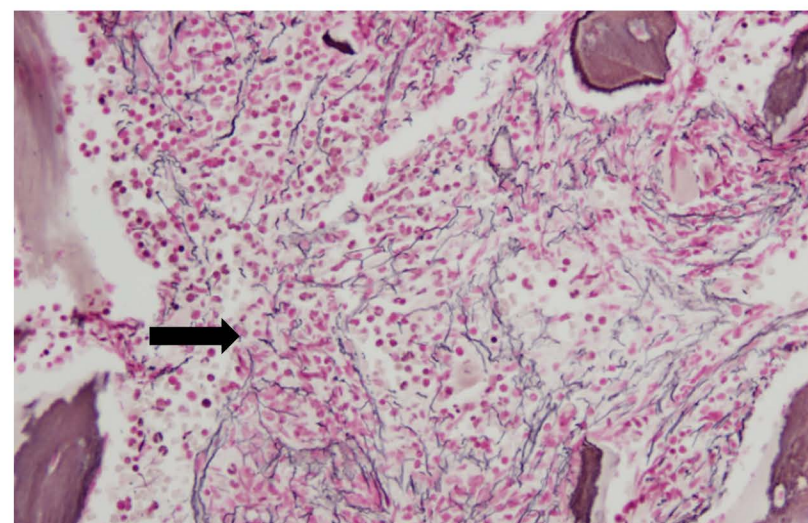
**B**



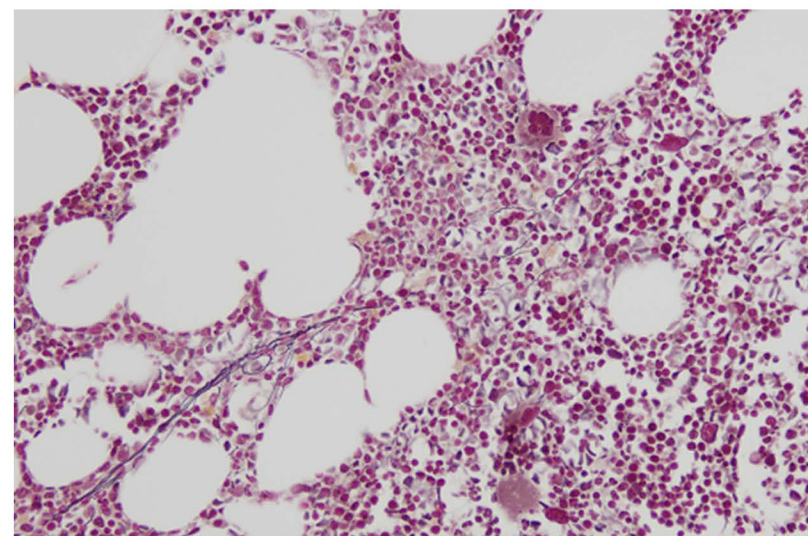
**D**



**E**



**F**







Prepublished online May 21, 2018;  
doi:10.1182/blood-2017-12-824433

## **Syndromic congenital myelofibrosis associated with a loss-of-function variant in RBSN**

Pilar L. Magoulas, Oleg A. Shchelochkov, Matthew N. Bainbridge, Shay Ben-Shachar, Svetlana Yatsenko, Lorraine Potocki, Richard Alan Lewis, Charles Searby, Andrea N. Marcogliese, M. Tarek Elghetany, Gladys Zapata, Paula Patricia Hernández, Manasi Gadkari, Derek Einhaus, Donna M. Muzny, Richard A. Gibbs, Alison A. Bertuch, Daryl A. Scott, Silvia Corvera and Luis M. Franco

---

Information about reproducing this article in parts or in its entirety may be found online at:  
[http://www.bloodjournal.org/site/misc/rights.xhtml#repub\\_requests](http://www.bloodjournal.org/site/misc/rights.xhtml#repub_requests)

Information about ordering reprints may be found online at:  
<http://www.bloodjournal.org/site/misc/rights.xhtml#reprints>

Information about subscriptions and ASH membership may be found online at:  
<http://www.bloodjournal.org/site/subscriptions/index.xhtml>

---

Advance online articles have been peer reviewed and accepted for publication but have not yet appeared in the paper journal (edited, typeset versions may be posted when available prior to final publication). Advance online articles are citable and establish publication priority; they are indexed by PubMed from initial publication. Citations to Advance online articles must include digital object identifier (DOIs) and date of initial publication.