

Phomopsis bougainvilleicola Prepatellar Bursitis in a Renal Transplant Recipient

Paloma F. Cariello,^a Brian L. Wickes,^b Deanna A. Sutton,^c Lisa A. Castlebury,^d Stuart M. Levitz,^a Robert W. Finberg,^a Elizabeth H. Thompson,^c Jennifer S. Daly^a

Division of Infectious Diseases and Immunology, Department of Medicine, University of Massachusetts, Worcester, Massachusetts, USA^a; Department of Microbiology and Immunology^b and Department of Pathology,^c University of Texas Health Science Center, San Antonio, Texas, USA; USDA ARS Systematic Mycology & Microbiology Laboratory, Beltsville, Maryland, USA^d

Prepatellar bursitis is typically a monomicrobial bacterial infection. A fungal cause is rarely identified. We describe a 61-year-old man who had received a renal transplant 21 months prior to presentation whose synovial fluid and surgical specimens grew *Phomopsis bougainvilleicola*, a pycnidial coelomycete.

CASE REPORT

A 61-year-old man with chronic renal disease secondary to diabetic nephropathy and hypertensive nephrosclerosis underwent deceased-donor kidney transplantation 21 months prior to presentation. His posttransplant course was uncomplicated, although he had a history of gout, hepatitis C (genotype 1a), and coronary artery disease. Although the patient received therapy for hepatitis C with ribavarin and interferon prior to transplantation, he did not have a sustained virologic response and his hepatitis C virus load was 227,754 IU/ml 2 months before transplantation. The patient developed right knee pain for 2 days and then sought care. Immunosuppressive agents included tacrolimus, mycophenolate, and prednisone, none of which had been recently changed. He was a retired carpenter and auto mechanic who was born in Puerto Rico but had been living in mainland United States since childhood.

On physical examination, he was in no apparent distress and was afebrile with marked edema and erythema of the right knee. He had inability to flex his knee beyond 30 degrees due to excruciating pain. The remainder of the examination was unremarkable.

Laboratory evaluation showed a complete blood count that was within normal limits (white blood cell count of 6,100/mm³, hemoglobin of 14.8 g/dl, hematocrit of 45.1%, and platelet count of 178,000/mm³), C-reactive protein of 20.1 mg/liter, and an erythrocyte sedimentation rate of 23 mm/h. Ultrasonography showed a heterogeneous collection in the prepatellar superficial subcutaneous tissue. Magnetic resonance imaging demonstrated marked thinning and surface irregularity of the patellar cartilage with full-thickness cartilage loss at the patellar apex and associated subchondral bone marrow edema and intact bones (Fig. 1), consistent with prepatellar bursitis. A chest X-ray did not show any evidence of pulmonary disease.

Arthrocentesis revealed red and cloudy synovial fluid with 232,000 white blood cells, predominantly neutrophils; no crystals were seen. After arthrocentesis, empirical therapy with vancomycin and ceftriaxone was initiated to cover the most likely organisms. However, fluid reaccumulated, requiring repeated arthrocenteses followed, 5 days later, by surgical drainage in the operating room, where purulent material under pressure and inflamed synovial tissue were found.

The same filamentous fungus grew in six different specimens from the percutaneous aspirates and from the operating room tissue. Culture from the initial aspirate was planted on thioglycolate broth, trypticase soy agar (TSA) with 5% sheep blood, chocolate agar, and MacConkey agar. The routine culture was positive 4 days later and grew on TSA and chocolate agar at 35°C in 5% CO₂. The fungal culture grew on Sabouraud agar at 30°C and also at 25°C. The mycobiotic slant was negative. Subsequent irrigation and debridement was performed; tissue from the operating room had evidence of hyphae seen on a direct calcofluor stain with no identifiable structures. The fungus could not be identified by routine laboratory methodology, but it was later identified by DNA sequencing as *Phomopsis bougainvilleicola*. *In vitro* antifungal susceptibility testing was performed at ARUP Laboratories using full-range MIC testing and revealed the following MICs: amphotericin B, 1 µg/ml; anidulafungin, 0.12 µg/ml; caspofungin, 0.12 µg/ml; itraconazole, 0.5 µg/ml; micafungin, ≤0.6 µg/ml; posaconazole, ≤0.06 µg/ml; and voriconazole, 0.5 µg/ml.

The patient was treated with voriconazole for a total of 4 months. Serum concentrations measured by high-performance liquid chromatography at 1 and 2 months showed peak concentrations of 10.7 µg/ml and 12.6 µg/ml, respectively. Trough concentrations showed detectable levels at 6 weeks (4.7 µg/ml), at 3 months (4.3 µg/ml), and at the end of therapy at 4 months (3.8 µg/ml), with a target reference range of 1.0 to 5.5 µg/ml. A follow-up X-ray at 3 months showed no evidence of osteomyelitis. At the end of therapy, C-reactive protein normalized to 9.3 mg/liter (upper normal limit, 10 mg/liter) and the erythrocyte sedimentation rate remained elevated at 34 mm/h.

Fungal identification. Two synovial fluid isolates were referred to the Fungus Testing Laboratory (University of Texas Health Science Center, San Antonio, TX) for identification and

Received 4 October 2012. Returned for modification 24 October 2012.

Accepted 21 November 2012.

Published ahead of print 28 November 2012.

Address correspondence to Paloma F. Cariello, paloma.cariello@umassmemorial.org.

Copyright © 2013, American Society for Microbiology. All Rights Reserved.

doi:10.1128/JCM.02674-12

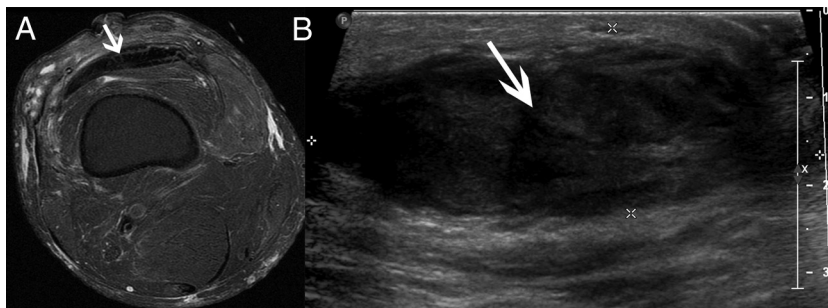


FIG 1 (A) Magnetic resonance imaging (axial view): 5.6-by-4.2-by-1.3-cm anterior loculated fluid collection and diffuse edema. (B) Ultrasonography: 5.8-by-2.1-cm heterogeneous collection in prepatellar area.

were added to their culture collection as isolates UTHSC 11-1155 and 11-1180, respectively. Slide cultures were prepared on potato flake agar, and additional subcultures were made using carnation leaf agar (CLA) and media containing cycloheximide (all prepared in-house and incubated at 25°C). Isolates failed to grow on media containing cycloheximide after 7 days. Slide cultures remained sterile, producing only a few chlamydoconidia after 2 weeks. CLA plates, however, produced triangular, erumpent (bursting through the surface) pycnidia (asexual fruiting structures) (Fig. 2), liberating their conidia in a cream-colored “ooze” from the ostiole (opening) after 3 weeks (Fig. 3A). Conidia were hyaline and of one type and guttulate (typically containing two small droplets or guttules inside each conidium), measuring 2 by 8 to 10 μm . At this point, the isolate was reported as a pycnidial coelomycete and sequencing was recommended for further identification. As the two isolates appeared to be identical, only UTHSC 11-1180 was sequenced under accession number R-4745. Subsequent subcultures of the isolate revealed short oblong conidia containing 0 to 2 oil-like droplets, termed alpha conidia, as well as long, filiform, curved conidia, known as beta conidia, measuring approximately 0.5 to 1 by 20 to 25 μm (Fig. 3B). UTHSC isolate number 11-1180 (R-4745) has been deposited in the University of Alberta Microfungus Collection under accession number UAMH 11634.

DNA sequencing. Template DNA from isolate R-4745 was recovered as described previously (1) using Prepman Ultra reagent (Applied Biosystems, Foster City, CA) to lyse cells. Template DNA was amplified and sequenced using the internal transcribed spacer 1 (ITS1), ITS4, NL1, and NL4 primers to yield the ITS sequences and D1 and D2 sequences as described previously (1). The *EF1- α* gene sequence was obtained by PCR and sequenced as described

previously (2). Sequencing was performed at the UTHSCSA Advanced Nucleic Acids Core Facility and used to search the GenBank database at <http://www.ncbi.nih.gov> using the BLASTn search algorithm. Sequence-based identities with a cutoff of 97% or greater and query coverage of >90% were considered significant. The best hit was defined as the sequence with the highest maximum identity to the query sequence.

Molecular identification. ITS sequences for representative species of *Phomopsis* (sexual state *Diaporthe*) were obtained from GenBank and aligned using MAFFT (<http://mafft.cbrc.jp/alignment/software/>). Maximum likelihood phylogenetic analysis of the ITS regions using PhyML (3) placed isolate 11-1180 in a clade containing *Phomopsis bougainvilleicola*, a relatively recently described species from China, with 100% bootstrap support. Additional isolates in the clade have been collected from various plant hosts from the United States, Puerto Rico, and Jamaica (Fig. 4). *Phomopsis averrhoae* is also included in this clade; however, as it is a later name, we consider *P. bougainvilleicola* to be the correct name for this clade. Analysis of the *EF1- α* gene region using NCBI BLAST found a 97% match over 98% coverage with an unidentified *Phomopsis* isolate from mangrove in China (EU259179), with *P. phoenicicola* (GQ250349) as the next closest match.

In most patients, including transplant recipients, septic arthritis and bursitis are typically caused by monomicrobial bacterial infections. A fungal cause is rarely identified. Cases of fungal infection in the literature have been reported after penetration of

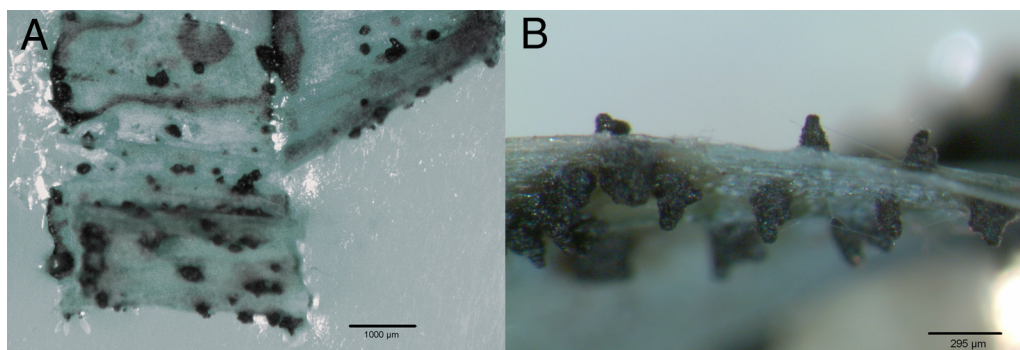


FIG 2 (A) Pycnidia on carnation leaf agar after 3 weeks of incubation at 25°C in ambient air; (B) closeup of triangular, erumpent pycnidia on carnation leaf agar.

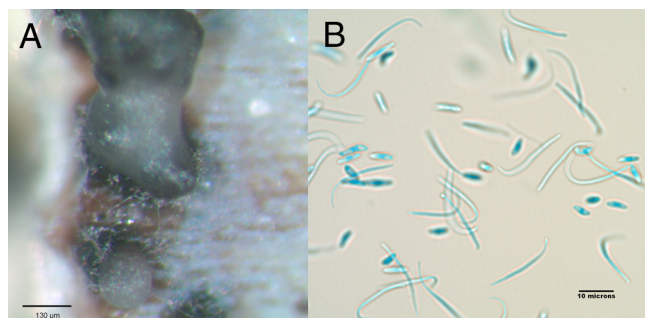


FIG 3 (A) Conidia being liberated in an “ooze” from an ostiole (opening) in the pycnidium; (B) short oblong alpha conidia containing 0 to 2 oil droplets and long, filiform, curved beta conidia.

soft tissue injuries with organic matter, but these are rare. Our patient’s case illustrates the need to pursue both laboratory identification and antifungal susceptibility testing to provide the best therapy for patients with invasive fungal infection.

Coelomycetes are fungi that produce their conidia within several different types of asexual fruiting structures referred to as conidioma, one of which is a pycnidium, as opposed to the more

common fungi known as hyphomycetes, such as *Aspergillus* species, for example, which bear their conidia free to the air. They are inhabitants of branches and leaves of numerous host plants. Although highly prevalent in nature, they rarely cause human disease. The coelomycete genus *Phomopsis* contains melanized or dematiaceous fungus. Identification rarely goes beyond the genus level, and they are recognized by their black, pycnidial conidiomata (globose to subglobose structures lined with conidiogenous cells) that produce hyaline to pale brown mycelium with basic types of conidia: alpha (short and ellipsoidal) and beta (long, filiform, curved) (4, 5). There are rare reports of *Phomopsis* species identified as human pathogens in the literature. To our knowledge, this is the first reported case of human disease in which *Phomopsis bougainvilleicola* was identified. Initially identified only as a melanized pycnidial coelomycete, subsequent production of alpha and beta conidia, the hallmark of the genus, confirmed the presence of a *Phomopsis* sp. Definitive identification to the species level required DNA sequencing and comparison with the voucher strain.

Opportunistic mycoses are commonly caused by filamentous fungi such as *Aspergillus* spp. and *Fusarium* spp. bearing their conidia free. Coelomycete human disease is rarely reported; how-




FIG 4 Phylogenetic tree showing comparison with voucher strain.

ever, several genera have been recovered from clinical specimens (6). Infection is thought to be acquired by accidental inoculation of the fungus into subcutaneous tissue by pricking with thorns or spines of different plants, and it is more frequently described in people working in forest or rural areas. The infection may progress indolently for years or even decades.

The only 3 cases of *Phomopsis* causing human disease reported in the literature were a renal-transplant recipient patient with *Phomopsis longicolla* in a nodular lesion of the distal phalange (7), a *Phomopsis* sp. causing osteomyelitis in another immunosuppressed patient on prednisone and methotrexate for rheumatoid arthritis (5), and a case of fungal scleral keratitis caused by *Phomopsis phoenicicola* in a patient after pterygium surgery (removal of conjunctival tissue that has grown over the edge of the cornea) (8).

Our patient, however, did not report any direct trauma to the affected area, although he could have had remote inoculation of which he was unaware. In the other cases reported in immunosuppressed patients, there was a remarkable traumatic penetrating injury prior to transplantation, suggesting that a significant amount of organic matter was introduced and persisted in a subclinical or latent form (9). This implies that skin disruption and immunosuppression do not necessarily have to occur simultaneously and that subsequent immunosuppression may trigger an active infection.

As in other rare cases of invasive fungal disease in immunocompromised hosts, there was a prolonged period (21 months) of immunosuppression before development of disease. We were unable to identify a potential source or pinpoint the time of initial inoculation. Although the setting of his presentation was acute, it is plausible that he had acquired the infection years before and that immunosuppression after renal transplantation had allowed fungal growth. Dematiaceous mold infections are rare; however, they are increasing in the immunosuppressed host and must be considered in the differential diagnosis when a typical etiologic agent is not identified.

All reported cases of *Phomopsis* human disease were treated with surgical debridement (5, 7, 9) in addition to antifungal therapy. Recommendations for empirical therapy are difficult to make given the limited number of described cases, the paucity of *in vitro* susceptibility data, and the lack of guidelines for interpretation available from the Clinical and Laboratory Standards Institute (CLSI). Nevertheless, we advise performing susceptibility testing on patient isolates and obtaining drug levels with the goal of maintaining serum concentrations above the MIC. Other factors requiring consideration when administering antifungal drugs to transplant recipients include the necessity of achieving appropriate tissue penetration and drug-drug interactions. For example, azole antifungal drugs inhibit the metabolism of tacrolimus, an antirejection drug widely used in transplant recipients (10, 11). Painful periostitis with fluoride excess has also been described in posttransplant patients with long-term voriconazole use (12), and close management of the patient's clinical status and medication level is critical.

Organ transplantation has been performed with an increasing frequency worldwide, increasing the number of patients on immunosuppressive therapy. This has given rise to unusual clinical forms of superficial and invasive fungal infections. Practitioners should be aware and mindful of the possibility of these fungal infections when evaluating such patients. Our patient showed a good response with a combination of antifungal and surgical therapy, and no recurrence was noted for at least 15 months after the discontinuation of antifungal therapy.

Nucleotide sequence accession numbers. Sequences determined in this work were deposited in GenBank under accession numbers JX847139, JX847137, and JX847138 for ITS, D1 and D2, and *EF1-α*, respectively.

ACKNOWLEDGMENT

We thank Brenda B. Torres, Manager of Microbiology Laboratories, University of Massachusetts, for her help with the manuscript.

REFERENCES

- Romanelli AM, Sutton DA, Thompson EH, Rinaldi MG, Wickes BL. 2010. Sequence-based identification of filamentous basidiomycetous fungi from clinical specimens: a cautionary note. *J. Clin. Microbiol.* 48: 741–752.
- Schilder AMC, Erincik O, Castlebury L, Rossman A, Ellis MA. 2005. Characterization of *Phomopsis* spp. infecting grapevines in the Great Lakes region of North America. *Plant Dis.* 89:755–762.
- Guindon S, Dufayard JF, Lefort V, Anisimova M, Hordijk W, Gascuel O. 2010. New algorithms and methods to estimate maximum-likelihood phylogenies: assessing the performance of PhyML 3.0. *Syst. Biol.* 59:307–321.
- Revankar SG, Sutton DA. 2010. Melanized fungi in human disease. *Clin. Microbiol. Rev.* 23:884–928.
- Sutton DA, Timm WD, Morgan-Jones G, Rinaldi MG. 1999. Human phaeohyphomycotic osteomyelitis caused by the coelomycete *Phomopsis saccharo* 1905: criteria for identification, case history, and therapy. *J. Clin. Microbiol.* 37:807–811.
- Sutton DA. 1999. Coelomycetous fungi in human disease. A review: Clinical entities, pathogenesis, identification and therapy. *Rev. Iberoam. Micol.* 16:171–179.
- Garcia-Reyne A, Lopez-Medrano F, Morales JM, Garcia Esteban C, Martin I, Erana I, Meije Y, Lalueza A, Alastruey-Izquierdo A, Rodriguez-Tudela JL, Aguado JM. 2011. Cutaneous infection by *Phomopsis longicolla* in a renal transplant recipient from Guinea: first report of human infection by this fungus. *Transpl. Infect. Dis.* 13:204–207.
- Gajjar DU, Pal AK, Parmar TJ, Arora AI, Ganatra DA, Kayastha FB, Ghodadra BK, Vasavada AR. 2011. Fungal scleral keratitis caused by *Phomopsis phoenicicola*. *J. Clin. Microbiol.* 49:2365–2368.
- Marty FM, Petschnigg EM, Hammond SP, Ready JE, Ho VT, Soiffer RJ, Magee C, Milner DA, Antin JH, Baden LR. 2011. Invasive fungal disease after remote inoculation in transplant recipients. *Clin. Infect. Dis.* 52:e7–e10.
- Capone D, Tarantino G, Gentile A, Sabbatini M, Polichetti G, Santangelo M, Nappi R, Ciotola A, D'Alessandro V, Renda A, Basile V, Federico S. 2010. Effects of voriconazole on tacrolimus metabolism in a kidney transplant recipient. *J. Clin. Pharm. Ther.* 35:121–124.
- Dodds-Ashley E. 2010. Management of drug and food interactions with azole antifungal agents in transplant recipients. *Pharmacotherapy* 30:842–854.
- Wermers RA, Cooper K, Razonable RR, Deziel PJ, Whitford GM, Kremers WK, Moyer TP. 2011. Fluoride excess and periostitis in transplant patients receiving long-term voriconazole therapy. *Clin. Infect. Dis.* 52:604–611.