

Stroke

American Stroke
AssociationSM

JOURNAL OF THE AMERICAN HEART ASSOCIATION

A Division of American
Heart Association



Polyglycolide/Poly lactide-Coated Platinum Coils for Patients With Ruptured and Unruptured Cerebral Aneurysms: A Single-Center Experience

Italo Linfante, Nabil M. Akkawi, Alain Perlow, Vincenzo Andreone and Ajay K. Wakhloo

Stroke 2005;36:1948-1953; originally published online Jul 28, 2005;

DOI: 10.1161/01.STR.0000177532.94736.85

Stroke is published by the American Heart Association, 7272 Greenville Avenue, Dallas, TX 75214
Copyright © 2005 American Heart Association. All rights reserved. Print ISSN: 0039-2499. Online
ISSN: 1524-4628

The online version of this article, along with updated information and services, is
located on the World Wide Web at:

<http://stroke.ahajournals.org/cgi/content/full/36/9/1948>

Subscriptions: Information about subscribing to Stroke is online at
<http://stroke.ahajournals.org/subscriptions/>

Permissions: Permissions & Rights Desk, Lippincott Williams & Wilkins, a division of Wolters
Kluwer Health, 351 West Camden Street, Baltimore, MD 21202-2436. Phone: 410-528-4050. Fax:
410-528-8550. E-mail:
journalpermissions@lww.com

Reprints: Information about reprints can be found online at
<http://www.lww.com/reprints>

Polyglycolide/Poly lactide-Coated Platinum Coils for Patients With Ruptured and Unruptured Cerebral Aneurysms

A Single-Center Experience

Italo Linfante, MD; Nabil M. Akkawi, MD; Alain Perlow, MD;
Vincenzo Andreone, MD; Ajay K. Wakhloo, MD, PhD

Background and Purpose—Recanalization of cerebral aneurysm is a limitation of bare platinum coils (BPCs). In a swine aneurysm model, polyglycolide/poly lactide (a polymer)-coated platinum coils (Matrix) accelerated clot fibrosis and reduced recanalization rate and aneurysmal volume. We aimed to evaluate the safety of Matrix coils in patients with intracranial aneurysm.

Methods—This is a single-center, prospective study of patients with intracranial aneurysms treated with Matrix alone or in combination with BPCs. Follow-up evaluation included a 1-month clinical evaluation and a 6- and 12-month clinical and angiographic examination. Primary adverse events included death, stroke, and permanent neurological deficits.

Results—Between May 2002 and January 2004, 52 patients (range 34 to 79 years of age; 38 females) were treated for 54 aneurysms (size 7.9 ± 4.6 mm; neck 3.9 ± 1.5 mm; 26 ruptured). Matrix alone was used in 13 aneurysms. In 39, we used a combination of Matrix and BPCs. Twenty-one aneurysms had a 6-month follow-up examination (11 Matrix; 10 Matrix combined with bare platinum), and 11 completed the 12-month follow-up evaluation (Matrix only). Adverse events not related to the procedure were 2 deaths (ruptured basilar aneurysms) and 1 stroke at day 10 postcoiling secondary to vasospasm. Procedure-related adverse events were 2 strokes. At 6-month follow-up (n=21) evaluation, 2 of 3 recanalizations needed retreatment. At 12-month follow-up (n=11), there was no recanalization in patients treated with Matrix alone and no significant reduction in aneurysmal size.

Conclusions—Polyglycolide/poly lactide-coated coils had a satisfactory safety profile. Significant aneurysmal size reduction after coiling was not observed. (*Stroke*. 2005;36:1948-1953.)

Key Words: angiography ■ cerebral aneurysm ■ polymers ■ subarachnoid hemorrhage

Endovascular therapy using detachable coils significantly improves outcome compared with traditional surgery in patients with ruptured and unruptured intracranial aneurysms.¹⁻⁵ In particular, the International Subarachnoid Aneurysm Trial (ISAT) reported a relative risk reduction of death or dependency at 1 year of 22.6% versus microsurgical clipping.³ The main drawback of embolization with bare platinum coils (BPCs) is aneurysmal recanalization occurring in up to 40% of patients.⁶⁻¹⁴

Platinum is a biologically inert material. As such, it produces a delayed clot organization and no inflammatory response. This phenomenon may be responsible for aneurysm recanalization after coil embolization, in particular, in broad-necked or giant aneurysms.^{7,12} Several strategies have been used to reduce the percentage of aneurysms that recanalize, such as: (1) increased packing density; (2) use of radioactive coils and coils coated with bioabsorbable polymeric material

(BPM);^{15,19} (3) cytokines such as growth factors,²⁰ ion implantation, and protein coating;²¹ and (4) fibroblast tissue allografts.^{11,22} In particular, BPMs can stimulate the cellular reaction necessary to promote scar formation in the aneurysm. This biological reaction can be controlled by the composition of the copolymers.

Polymer-coated platinum coils (Matrix; BSC/Target) are platinum coils covered with a bioabsorbable polymer (90% polyglycolide, 10% poly lactide). The composition of BPM is similar to surgical suture material. Such material is then wrapped and attached to a stainless-steel delivery wire. Murayama et al in a swine model reported reduced rate of recanalization and a decrease in size of the aneurysmal sac in aneurysms treated with Matrix.¹⁵

We present our clinical and angiographic follow-up data in patients with ruptured and unruptured intracranial aneurysms treated with 90% polyglycolide-coated and 10% poly lactide-coated platinum coils (Matrix).

Received May 11, 2005; final revision received June 15, 2005; accepted June 28, 2005.

From the Section of Neuroimaging and Intervention, Department of Radiology (I.L., N.M.A., A.K.W.), University of Massachusetts, Worcester; Kalamazoo Radiology Associates (A.P.), Kalamazoo, Michigan; and the Department of Neurology (V.A.), Cardarelli Hospital, Naples, Italy.

Correspondence to Italo Linfante, MD, Section of Neuroimaging and Intervention, Department of Radiology and Neurology, University of Massachusetts, Memorial University Campus, 55 Lake Avenue North, Worcester, MA 01655. E-mail linfanti@ummhc.org

© 2005 American Heart Association, Inc.

Stroke is available at <http://www.strokeaha.org>

DOI: 10.1161/01.STR.0000177532.94736.85

Patients and Methods

This is a single-center, prospective, safety and feasibility study in which patients were treated with bioabsorbable polymer (polyglycolide and polylactide)-coated coils (Matrix) alone or in combination with BPCs. Inclusion criteria for the study were patients >18 years of age with either ruptured or unruptured aneurysms. The study was approved by our institutional review board. Informed consent for the procedure was obtained by the patient whenever possible or by the closest family member if the patient was unable to understand the risks or benefits of the procedure.

Angiographic Procedure

All diagnostic angiograms were discussed with the vascular neurosurgeon to decide the best approach to the lesion (ie, endovascular embolization versus microsurgical clipping). Criteria that would favor an endovascular approach were: (1) age (>50 years old); (2) size; (3) location (posterior circulation); (4) unruptured; (5) if ruptured, presence of vasospasm; (6) poor grade; and (7) operator preference or availability.

Patients underwent general anesthesia for the procedure. Access was obtained via the common femoral artery in all patients. We used standard angiographic procedure for coil embolization. Endovascular treatment was performed on a biplane angiography unit with 3D capability (Artis; Siemens). A Prowler 14-microcatheter (Cordis Neurovascular; J&J) over either an Agility 10, 14 (Cordis Neurovascular; J&J), or Synchro 10 or 14 microwire (Boston Scientific/Target) was advanced through a guiding catheter. The tip of the microcatheter was positioned in the dome of the aneurysm. Before coil embolization, dimensions of the aneurysm were obtained in ≥ 4 projections, and reconstructions in 3 dimensions were obtained in most patients. The interventionalists could always choose any other coil system from the inventory if they believed it would be safer, more effective, or more appropriate for each coil deposition. We used the Matrix detachable coil preparation commercially available. Matrix is a platinum coil covered with a bioabsorbable polymer (90% polyglycolide, 10% polylactide). The details of the coil characteristics and the detachment system were described previously.^{15,17,18} All aneurysms were densely packed using either Matrix coils alone or a combination of Guglielmi detachable coils (GDCs; Boston Scientific/Target) or Detachable Coil System (Cordis Neurovascular; J&J) coils. After the treatment, patients were admitted to the neurosurgical intensive care unit.

Clinical Evaluation

A neurological examination was performed in all patients at baseline, immediately after the procedure, and at 6 and 12 months after coil embolization. The modified Rankin scale was included in the 30-day and 6-month follow-up evaluations. Primary adverse events included death and stroke. Secondary adverse events recorded were transient ischemic attack, need for reintervention, and presence of hematomas. Residual aneurysmal size was determined by angiography. Medical histories, procedural reports, and clinical outcomes were recorded in a prospective database maintained for quality assurance purposes by the Interventional Neuroradiology Service.

The guideline for stopping the study was an incidence of primary adverse events that exceeded twice the rate of such events reported in ISAT and International Study of Unruptured Intracranial Aneurysms (ISUIA).^{3,5}

Aneurysmal Volume

Aneurysmal size was measured after obtaining ≥ 4 angiographic projections. Reconstructions in 3 dimensions were obtained in most patients. Aneurysmal volume was calculated using the ellipsoid, cylindrical, spherical, or conical volume equations. Packing density was calculated as the ratio of coil volume to aneurysmal volume. To evaluate whether Matrix was able to decrease the aneurysmal size, we calculated the diameters of the aneurysmal sac in ≥ 2 perpendicular angiographic projections. Such measurements were obtained at baseline and at follow-up angiography. In addition, we calculated aneurysmal volume using the ellipsoid, cylindrical, spherical, or

conical volume equations. Packing density was calculated as the ratio of coil volume to aneurysmal volume.

Angiographic Follow-Up

Angiographic follow-up studies were scheduled at 3 months. Twenty-one aneurysms had a 6-month follow-up examination (11 Matrix; 10 Matrix combined with bare platinum), and 11 completed the 12-month follow-up evaluation (Matrix only). For comparative reasons, follow-up studies were performed in same projections as the pre-embolization angiograms. Anatomic results were classified as published previously.^{7,15} In particular, results were divided into 3 classes: (1) complete obliteration; (2) residual neck, defined as the persistence of any portion of the original neck; and (3) residual aneurysm, defined as any opacification of the aneurysm sac. At follow-up angiography, a recurrence was defined as any increase in the size of the remnant. The recurrence was qualified as major if its size would require a treatment with coils or a surgical clipping.

Statistical Analysis

Values were expressed as mean and SD. Comparisons between groups and between aneurysmal volumes were performed with paired and unpaired Student *t* test analysis and χ^2 . The significance level was pre-established at $P \leq 0.05$.

Results

Between May 2002 and January 2004, 52 patients (age range 34 to 79 years; 38 females) were treated for 54 aneurysms (size 7.9 ± 4.6 mm; neck 3.87 ± 1.5 mm; 26 ruptured; Table 1). Thirteen aneurysms were treated with Matrix alone and the remaining with a combination of Matrix plus other coils. Satisfactory coiling of the aneurysm was achieved in all but 3 aneurysms, which were left with minimal contrast filling. In 25% of our cases, a balloon remodeling technique was used as described previously for safer coil embolization.^{23,24}

Stroke related to the procedure was observed in 2 patients: 1 stroke occurred at day 2 (patient treated with a combination of matrix and BPCs) and the other at day 21 after embolization (Matrix only). Adverse events not related to the procedure were 2 deaths in patients with a rupture basilar tip aneurysm who had a pre-embolization Hunt and Hess grade 5. There was also 1 stroke at day 10 secondary to severe vasospasm (Table 1).

Twenty-one aneurysms completed the 3- to 6-month follow-up evaluation (11 Matrix; 10 Matrix plus other systems), and 11 completed the 12-month follow-up evaluation (Matrix only; Figure 1). Overall, there have been no deaths or aneurysmal rupture during the follow-up period. At 3- to 6-month ($n=21$) angiographic follow-up evaluation, there was 1 recurrence secondary to insufficient Matrix coil supply. At the time of follow-up evaluation, a coil embolization of the remnant aneurysmal sac was successfully accomplished (Figure 2). There was 1 aneurysm with center filling (treated with a combination of Matrix and BPC) possibly secondary to concomitant therapy with aspirin plus clopidogrel for 6 months. One aneurysm showed coil compaction probably secondary to insufficient packing density.

At the 12-month follow-up ($n=11$; Matrix alone), there was no recanalization of the treated aneurysms. In the 11 patients treated with Matrix alone, average coil packing density was 29% (Table 2). Nine patients had unruptured and 4 had ruptured aneurysms. Two patients experienced vasospasm during the initial procedure that improved with tripleH

TABLE 1. Demographic Data and Clinical Adverse Events in Patients With Cerebral Aneurysms and Treated With Matrix Coils Only or a Combination of Matrix and BPCs

	Age (mean±SD; years)	Sex (Male/ Female)	*Size Aneurysm (mean±SD; mm)	Neck Aneurysm (mean±SD; mm)	Ruptured/ Unruptured Aneurysm	Clinical Adverse Events (Postcoiling)		Follow-Up
						Related to Procedure	Unrelated to Procedure	
Patients (n=52; 54 aneurysms)	55.9±12.9	14/38	7.9±4.6 S (23), M (20), L (11)	3.87±1.5 S (25), L (29)	26/28	2	2	
Matrix+BPC (n=39; 41 aneurysms)	56.3±13.9	9/30	8.1±4.6 S (18), M (16) L (7)	4.0±1.65 S (20) L (21)	22/19	1 stroke at day 2	1 stroke at day 10 (vasospasm) 2 deaths (ruptured basilar aneurysms) (patients admitted with grade 5 H&H)	All survived at 3 months; 10 at 6 months
Matrix only (13 aneurysms)	55.1±9.7	5/8	7.4±5.1 S (5), M (4) L (4)	3.59±1.3 S (5) L (8)	4/9	1 stroke at day 21		All at 3 months; 11 at 12 months
<i>P</i>	NS†	NS‡	NS†	NS†	NS‡			

H&H indicates Hunt and Hess Scale.

For aneurysmal size, S indicates small (<5 mm); M, medium (5–10 mm); L, large (> 10 mm or neck).

For aneurysmal neck, S indicates small (<4 mm); L, large (>4 mm).

*Size is considered the largest diameter of the aneurysm in ≥2 perpendicular angiographic projections; †analysis based on unpaired Student's *t* test; ‡analysis based on χ^2 .

therapy. Five patients had residual neck not requiring retreatment (Figure 2). Opening of the aneurysm neck was noted in only 2 patients. Reduction of aneurysm size was not observed at 12-month follow-up in patients treated with Matrix alone (Table 3; Figures 1 and 2).

Discussion

In this preliminary experience, Matrix coils had a satisfactory safety profile. The procedure led to 1 stroke at day 2 and 1 stroke at day 21 after coil embolization. Adverse events unrelated to the procedure were 2 deaths in patients with ruptured basilar artery aneurysms (Hunt and Hess grade 5) and 1 stroke at day 10 because of severe vasospasm. At

6-month (n=21) angiographic follow-up evaluation, there were 3 aneurysms that recanalized (14.2%). At 12-month angiographic and clinical follow-up, there were no deaths or aneurysmal ruptures. A size reduction of aneurysms treated with Matrix coils alone was not observed.

The exact mechanism by which thrombosis and formation of neointimal proliferation after coil embolization is not known.²⁵ Platinum coils elicit a mild biological response when deployed into an aneurysm.²⁶ Tamatani et al reported no endothelial proliferation on the BPC surface in an in vitro study.¹⁹ From histopathologic reports on human aneurysms embolized with GDC, it appears that the intra-aneurysmal clot undergoes a slow organization.^{12,19} Therefore, when such

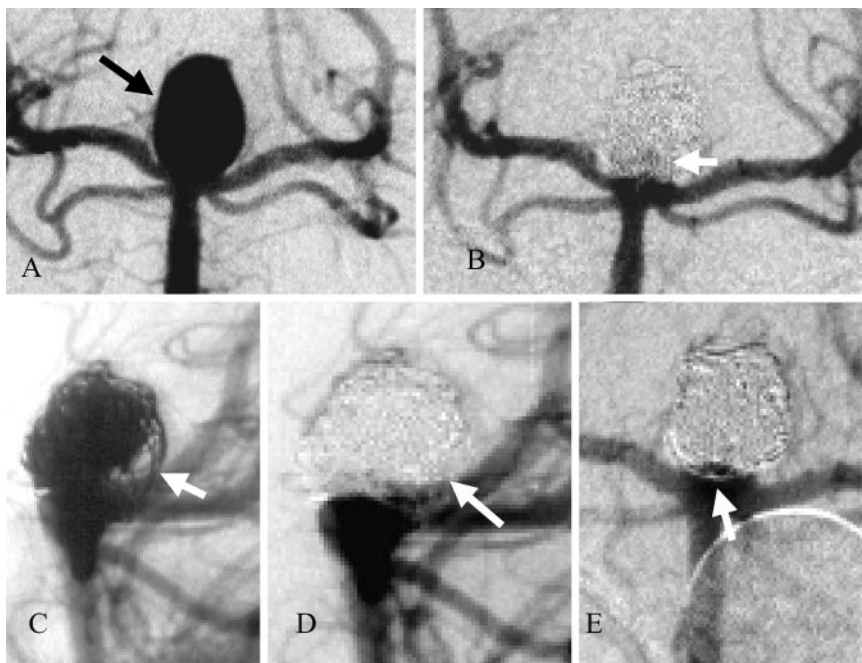


Figure 1. Case example. 42-year-old woman with a rupture basilar tip aneurysm. A, Anteroposterior view of the left vertebral artery (VA) injection. B, Anteroposterior view of the left VA injection after embolization with Matrix coils alone shows mild contrast accumulation at the base (white arrow). 3-month follow-up angiogram: nonsubtracted lateral view shows the coil mass with large gaps between the coils (white arrow [C]) and subtracted view shows no contrast filling between the coils because it has most likely been replaced by connective tissue (white arrow; D). 12-month follow-up angiogram: anteroposterior view of the left VA injection demonstrating coil compaction at the neck and no recanalization of the aneurysm (white arrow; E). There was no reduction in aneurysmal size between the pre-embolization and postembolization angiogram.

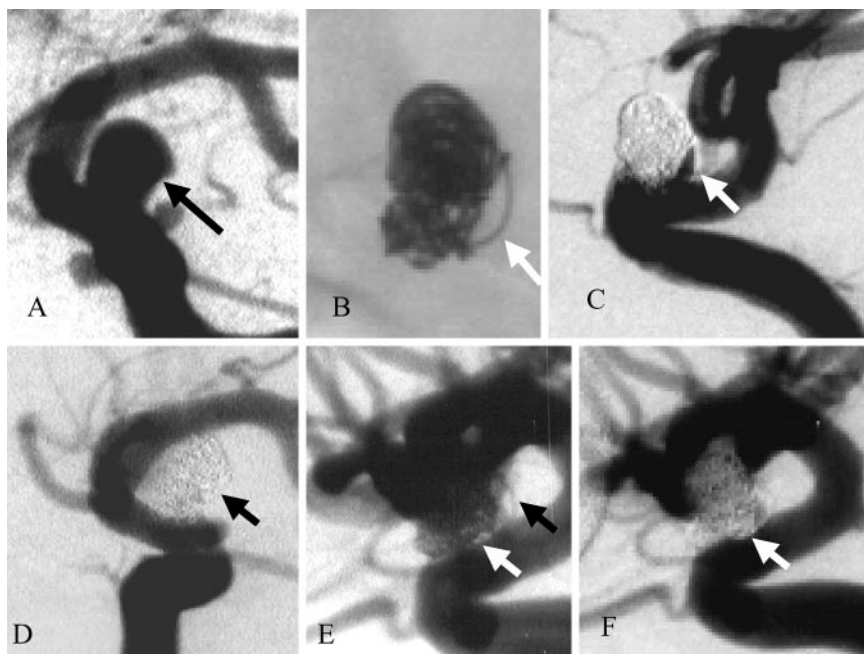


Figure 2. Case example. 62-year-old woman with an unruptured left supraclinoid internal carotid artery (ICA) aneurysm treated with Matrix coils alone. A, Left magnified oblique view of the left ICA injection before embolization (black arrow). B, 3-month follow-up: non-subtracted view of the coil mass showed a large coil gap between the coils in the posterior portion of the aneurysmal sac (white arrow). This resulted in persistent filling of the aneurysm after coiling with “dog ear” appearance (C). 12-month follow-up: left ICA injection in left lateral oblique view shows no contrast filling between the coil mass because it has most likely been replaced by connective tissue (black arrow; D and E). Non-subtracted (E) and subtracted (F) view of a left lateral oblique ICA angiogram shows formation of a membrane at the neck of the aneurysm (white arrows). There was no reduction in aneurysmal size between the pre-embolization and postembolization angiogram.

phenomena do not occur, the effect of pulsatile blood flow against inert platinum causes the coil mass to compact, leading to eventual aneurysmal recanalization.^{25,27} For all these reasons, investigators have explored the use of coils that promote organization of the initial thrombus such as polymer-coated coils and radioactive coils.^{15,16}

With regard to polymer-coated coils, it has been reported that aneurysm thrombosis could be controlled by the composition of the polymer ratio.^{28–29} As the polymer degrades, it produces a mild inflammatory reaction. In a swine model, Murayama et al showed that Matrix-treated aneurysms presented an average of 87% of their area as organized thrombus versus an average of 75% in the aneurysms treated with BPCs.¹⁵ Histologically, bioabsorbable polymer was replaced by mature connective tissue. The authors reported that mature scar tissue by the process of wound healing decreases the size of the aneurysm.

TABLE 2. Aneurysmal Volume, Coil Volume, and Packing Density of Aneurysms Treated With Matrix Only

Patients	Aneurysm Volume (mm ³)	Coil Volume (mm ³)	Packing Density (%)
1	157.8	32.9	20.9
2	322.8	82.0	25.4
3	11.10	3.2	28.9
4	58.90	9.6	16.3
5	525.0	144.7	27.5
6	1796.9	315.2	17.5
7	7.6	4.8	63.3
8	13.1	5.2	27.9
9	2280.3	506.6	22.2
10	15.7	6.4	40.9
11	634.4	130.2	20.5
Mean±SD	634.4±784.6	112.8±161.8	29.0±13.1

In our small case series of 11 patients treated with matrix alone, we did not replicate such findings (Table 3; Figures 1 and 2). The experimental observation may be related to less packing density of the aneurysm in the Matrix group compared with the bare platinum-treated side wall porcine aneurysm.¹⁵

In the present series, we observed individual variation in the amount of scarring tissue formation after embolization with Matrix coils. Neointimal growth or “white collar sign” was seen in 2 patients treated with Matrix coils alone (Figure 2).³⁰ On the other hand, this phenomena may lead to untoward parent artery stenosis or occlusion related to intra-aneurysmal clot formation and subsequent fibrosis. Excessive clot formation leading to stroke was observed in 2 patients. Fibrosis and subsequent stenosis of the parent arteries adjacent to the aneurysm was observed in another case. This observation needs careful evaluation in a larger cohort of patients.

Friction and compartmentalization were observed in our experience. Friction is probably related to the high amount of polymer (70%) supported by a small central wire (30%) as designed in the first generation Matrix coils. We hypothesize that the high percentage of polymer creates an increase in contact points between the coil and the inner surface of the catheter. Consequently, the axial force required to advance the coil is higher. With regard to compartmentalization, the polymer is braided over the wire, therefore not allowing break points within the coil to be active. This may result in less compliance of the coil as it folds against the endothelium of the aneurysm and other coils.

Regarding recanalization, in 1 patient treated with aspirin plus clopidogrel, we noted a center-filling defect. We hypothesized that the concurrent treatment of aggressive antiplatelet regimen may induce recanalization by preventing thrombus formation.

This preliminary study was not designed to assess efficacy. The recurrence rate in our small cohort is compatible with any

TABLE 3. Diameters of Aneurysmal Sac and Neck in Patients Treated With Matrix Coils Alone at Baseline and at 12-Month Angiographic Follow-Up Evaluation

Patients	Baseline			Follow-Up at 12 Months		
	Sac Height (mm)	Sac Width (mm)	Neck Width (mm)	Sac Height (mm)	Sac Width (mm)	Neck Width (mm)
1	7	5	4.5	6.3	5.1	3.4
2	9.4	6	3.5	9.6	6.8	3.2
3	2.5	2.5	2.2	2.5	2.3	2.1
4	5	4.5	5	3.1	3.6	3.4
5	11	8.4	3.7	11.5	9.4	6.6
6	16	14.3	4.1	15.4	14.7	0
7	2.6	2.8	2.5	2.5	2.8	2.5
8	3	3	2.7	3.1	3.4	1.8
9	17	13.5	5	21	16.4	0
10	2	4	2.2	2.4	5	2.9
11	9.6	9	6	11.8	11.5	7.4
Mean±SD	15.42±27.12	14.41±27.24	11.78±27.18	15.76±27.19	15.08±27.15	11.10±28.07

No significant difference was found between diameters at baseline and at follow-up (paired Student *t* test analysis).

hypothesis (success or failure in decreasing recurrences). In addition, we acknowledge that this pilot study has several weak points. (1) The total number of aneurysms is small. (2) Not all patients have long-term angiographic follow-up. (3) The study does not contain a control group with GDC procedure alone. (4) A comparison with clinical data on patients treated with Matrix is not yet available because most data are available only in an abstract form or in 2 cases reported recently.^{30–31}

Conclusions

Matrix coil has been the first attempt in using enhanced inflammatory response to reduce aneurysmal recanalization. This preliminary experience shows that polymer-coated coils may be a safe option in patients with ruptured and unruptured aneurysms. Individual excessive inflammatory response to Matrix coils resulting in untoward parent artery stenosis or occlusion may be observed and needs further investigation.

Acknowledgments

N.M.A. is supported from a grant of the “Centro di Studio e Ricerca sui Disturbi del Comportamento e delle Malattie Neurodegenerative, EULO, Department of Neurology, University of Brescia, Italy.”

References

- Guglielmi G, Vinuela F, Sepetka I, Macellari V. Electrothrombosis of saccular aneurysms via endovascular approach, I: electrochemical basis, technique, and experimental results. *J Neurosurg.* 1991;75:1–7.
- Guglielmi G, Vinuela F, Dion J, Duckwiler G. Electrothrombosis of saccular aneurysms via endovascular approach, II: preliminary clinical experience. *J Neurosurg.* 1991;75:8–14.
- Molyneux A, Kerr R, Stratton I, Sandercock P, Clarke M, Shrimpton J, Holman R. International Subarachnoid Aneurysm Trial (ISAT) of neurosurgical clipping versus endovascular coiling in 2143 patients with ruptured intracranial aneurysms: a randomized trial. *Lancet.* 2002;360:1267–1274.
- Vinuela F, Duckwiler G, Mawad M. Guglielmi detachable coil embolization of acute intracranial aneurysm: perioperative anatomical and clinical outcome in 403 patients. *J Neurosurg.* 1997;86:475–482.
- Anonymous. Unruptured intracranial aneurysms—risk of rupture and risks of surgical intervention. International Study of Unruptured Intracranial Aneurysms Investigators. *N Engl J Med.* 1998;10;339:1725–1733.
- Cognard C, Weill A, Spelle L, Piotin M, Castaing L, Rey A, Moret J. Long-term angiographic follow-up of 169 intracranial berry aneurysms occluded with detachable coils. *Radiology.* 1999;212:348–356.
- Raymond J, Guilbert F, Weill A, Georganos SA, Juravsky L, Lambert A, Lamoureux J, Chagnon M, Roy D. Long-term angiographic recurrences after selective endovascular treatment of aneurysms with detachable coils. *Stroke.* 2003;34:1398–1403.
- Ng P, Khangure MS, Phatouros CC, Bynevelt M, ApSimon H, McAuliffe W. Endovascular treatment of intracranial aneurysms with Guglielmi detachable coils: analysis of midterm angiographic and clinical outcomes. *Stroke.* 2002;33:210–217.
- Mizoi K, Yoshimoto T, Takahashi A, Nagamine Y. A pitfall in the surgery of a recurrent aneurysm after coil embolization and its histological observation: technical case report. *Neurosurgery.* 1996;39:165–168.
- Kallmes DF, Borland MK, Cloft HJ, Altes TA, Dion JE, Jensen ME, Hankins GR, Helm GA. In vitro proliferation and adhesion of basic fibroblast growth factor-producing fibroblasts on platinum coils. *Radiology.* 1998;206:237–243.
- Kallmes DF, Williams AD, Cloft HJ, Lopez MB, Hankins GR, Helm GA. Platinum coil-mediated implantation of growth factor-secreting endovascular tissue grafts: an in vivo study. *Radiology.* 1998;207:519–523.
- Bavzinski G, Talazoglu V, Killer M, Richling B, Gruber A, Gross CE, Plenck H Jr. Gross and microscopic histopathological findings in aneurysms of the human brain treated with Guglielmi detachable coils. *J Neurosurg.* 1999;91:284–293.
- Horowitz MB, Purdy PD, Burns D, Bellotto D. Scanning electron microscopic findings in a basilar tip aneurysm embolized with Guglielmi detachable coils. *AJNR Am J Neuroradiol.* 1997;18:688–690.
- Stiver SI, Porter PJ, Willinsky RA, Wallace MC. Acute human histopathology of an intracranial aneurysm treated using Guglielmi detachable coils: case report and review of the literature. *Neurosurgery.* 1998;43:1203–1208.
- Murayama Y, Tateshima S, Gonzalez NR, Vinuela F. Matrix and bioabsorbable polymeric coils accelerate healing of intracranial aneurysms: long-term experimental study. *Stroke.* 2003;34:2031–2037.
- Raymond J, Roy D, Leblanc P, Roorda S, Janicki C, Normandeau L, Morel F, Bahary JP, Chagnon M, Guilbert F, Weill A. Endovascular treatment of intracranial aneurysms with radioactive coils: initial clinical experience. *Stroke.* 2003;34:2801–2806.
- Murayama Y, Vinuela F, Tateshima S, Gonzalez NR, Song JK, Mahdavi H, Iruela-Arispe L. Cellular responses of bioabsorbable polymeric material and Guglielmi detachable coil in experimental aneurysms. *Stroke.* 2002;33:1120–1128.

18. Murayama Y, Vinuela F, Tateshima S, Song JK, Gonzalez NR, Wallace MP. Bioabsorbable polymeric material coils for embolization of intracranial aneurysms: a preliminary experimental study. *J Neurosurg.* 2001; 94:454–463.
19. Tamatani S, Ozawa T, Minakawa T, Takeuchi S, Koike T, Tanaka R. Histological interaction of cultured endothelial cells and endovascular embolic materials coated with extracellular matrix. *J Neurosurg.* 1997; 86:109–112.
20. Abrahams JM, Forman MS, Grady MS, Diamond SL. Delivery of human vascular endothelial growth factor with platinum coils enhances wall thickening and coil impregnation in a rat aneurysm model. *AJNR Am J Neuroradiol.* 2001;22:1410–1417.
21. Murayama Y, Vinuela F, Suzuki Y, Do HM, Massoud TF, Guglielmi G, Ji C, Iwaki M, Kusakabe M, Kamio M, Abe T. Ion implantation and protein coating of detachable coils for endovascular treatment of cerebral aneurysms: concepts and preliminary results in swine models. *Neurosurgery.* 1997;40:1233–1243.
22. Marx WE, Cloft HJ, Helm GA, Short JG, Do HM, Jensen ME, Kallmes DE. Endovascular treatment of experimental aneurysms by use of biologically modified embolic devices: coil-mediated intraaneurysmal delivery of fibroblast tissue allografts. *AJNR Am J Neuroradiol.* 2001; 22:323–333.
23. Moret J, Cognard C, Weill A, Castaings L, Rey A. Reconstruction technic in the treatment of wide-neck intracranial aneurysms. Long-term angiographic and clinical results. Apropos of 56 cases. *J Neuroradiol.* 1997; 24:30–44.
24. Mericle RA, Wakhloo AK, Rodriguez R, Guterman LR, Hopkins LN. Temporary balloon protection as an adjunct to endosaccular coiling of wide-necked cerebral aneurysms: technical note. *Neurosurgery.* 1997;41: 975–978.
25. Reul J, Weis J, Spetzger U, Konert T, Fricke C, Thron A. Long-term angiographic and histopathologic findings in experimental aneurysms of the carotid bifurcation embolized with platinum and tungsten coils. *AJNR Am J Neuroradiol.* 1997;18:35–42.
26. Molyneux AJ, Ellison DW, Morris J, Byrne JV. Histological findings in giant aneurysms treated with Guglielmi detachable coils: report of two cases with autopsy correlation. *J Neurosurg.* 1995;83:129–132.
27. Mawad ME, Mawad JK, Cartwright J Jr, Gokaslan Z. Long-term histopathologic changes in canine aneurysms embolized with Guglielmi detachable coils. *AJNR Am J Neuroradiol.* 1995;16:7–13.
28. Murayama Y, Vinuela F, Suzuki Y, Akiba Y, Ulihoa A, Duckwiler GR, Gobin YP, Vinters HV, Iwaki M, Abe T. Development of the biologically active Guglielmi detachable coil for the treatment of cerebral aneurysms, II: an experimental study in a swine aneurysm model. *AJNR Am J Neuroradiol.* 1999;20:1992–1999.
29. Murayama Y, Suzuki Y, Vinuela F, Kaibara M, Kurotobi K, Iwaki M, Abe T. Development of a biologically active Guglielmi detachable coil for the treatment of cerebral aneurysms, I: in vitro study. *AJNR Am J Neuroradiol.* 1999;20:1986–1991.
30. Gonzalez NR, Patel AB, Murayama Y, Vinuela F. Angiographic evidence of aneurysm neck healing following endovascular treatment with bioactive coils. *AJNR Am J Neuroradiol.* 2005;26:912–914.
31. Zaidat OO, Ionita C, Tolbert M, Graffagnino C, Alexander MJ, Durham NC. Endovascular cerebral aneurysm coil embolization using polymer coated (Matrix) detachable coils: preliminary single center experience of 181 aneurysms. Abstract presented at the American Academy of Neurology 57th Annual Meeting, Florida. 2005.