

Regional vitiligo induced by imiquimod treatment for in-transit melanoma metastases



Elizabeth Tkachenko, BS,^{a,b,c} Jennifer Y. Lin, MD,^{a,b} and Rebecca I. Hartman, MD, MPH^{a,b}
Boston and Worcester, Massachusetts

Key words: depigmentation; imiquimod; in-transit metastases; melanoma; vitiligo.

Imiquimod is a topical immunomodulator used for the treatment of viral warts and superficial basal cell carcinoma and as an emerging therapy for lentigo maligna and cutaneous melanoma metastases. Vitiligo-like depigmentation has been described as a local adverse effect of topical imiquimod therapy for melanoma¹ and at distant sites in patients treated with combination topical monobenzone-imiquimod for metastatic melanoma.² We present a case in which topical imiquimod resulted in both the resolution of in-transit metastatic melanoma and the depigmentation of local and regional skin, suggesting a regional lymphatic effect of this localized topical treatment.

CASE REPORT

A 78-year-old man presented with approximately 100 blue-black papules localized to the scalp that had been increasing in number. Punch biopsy found an atypical intradermal melanocytic proliferation with no intraepidermal component, consistent with in-transit stage IIIC metastatic melanoma. No primary lesion was noted by the patient or on clinical examination. Full-body positron emission tomography/computed tomography (CT) and brain magnetic resonance imaging found no evidence of metastatic disease. Imiquimod was initially chosen as a neoadjuvant treatment prior to surface brachytherapy because some of the patient's raised scalp lesions spontaneously flattened in the weeks after his presentation, suggesting an active immune response that could potentially be amplified. Two skin biopsies of flattened blue-black macules found tumoral melanosis with associated lymphocytic

Abbreviation used:

CT: computed tomography

infiltrates and no residual melanoma. He was subsequently treated with topical imiquimod 5% for 8 weeks, applying 1 packet daily for 2 weeks with an associated inflammatory response (Fig 1, A) and then increasing to twice-daily application for the next 6 weeks. All visible lesions were treated and appeared to respond clinically with flattening and reduction in dark coloration, although there were numerous residual blue-black macules on the scalp consistent with tumoral melanosis. Subsequent positron emission tomography/CT imaging found no evidence of malignancy. Brachytherapy was ultimately not required because of the robust response to topical imiquimod alone.

Fourteen months after treatment completion, he presented for routine surveillance. Scalp examination found improving blue-black macules, which were smaller and lighter in color compared with prior examinations (Fig 1, B). In addition, there were new well-demarcated depigmented patches on the scalp, neck, and head including the perioral region (Fig 2). Wood's light examination confirmed depigmentation. Full-body skin examination found no other depigmented lesions. There was no evidence of locoregional recurrence, and CT of the chest/abdomen/pelvis 1 month prior showed no evidence of metastatic disease. Three months later, however, seizures developed secondary to a hemorrhagic brain mass that was consistent with melanoma on

From the Department of Dermatology, Brigham and Women's Hospital^a; Harvard Medical School^b; and University of Massachusetts Medical School.^c

Funding sources: None.

Conflicts of interest: None disclosed.

Correspondence to: Rebecca I. Hartman, MD, MPH, Instructor of Dermatology, Harvard Medical School, BWH Department of Dermatology, 221 Longwood Avenue, Boston, MA 02215. E-mail: rhartman@bwh.harvard.edu.

JAAD Case Reports 2019;5:427-9.

2352-5126

Published by Elsevier on behalf of the American Academy of Dermatology, Inc. This is an open access article under the CC BY-NC-ND license (<http://creativecommons.org/licenses/by-nc-nd/4.0/>).

<https://doi.org/10.1016/j.jidcr.2019.03.015>

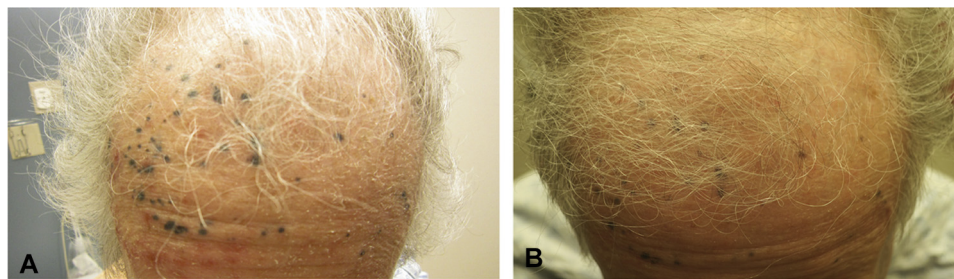


Fig 1. In-transit melanoma metastasis of the scalp. **A**, The patient's scalp after 2 weeks of imiquimod therapy, indicating the extent of cutaneous metastases and an inflammatory response to treatment. **B**, The patient's scalp 14 months after imiquimod treatment, demonstrating interval improvement as well as residual tumoral melanosis.

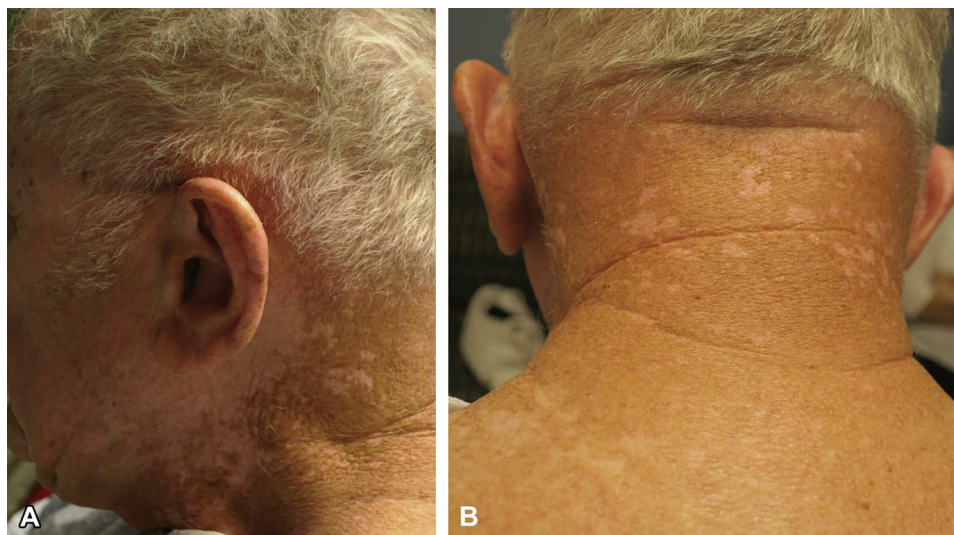


Fig 2. Imiquimod-induced vitiligo. Periauricular (**A**) and posterior neck (**B**) depigmentation representing regional vitiligo away from the site of topical imiquimod application, which was confined to the scalp at sites of cutaneous metastases.

pathology findings. He is status post—surgical resection and radiation, and currently receiving nivolumab. He has not had any additional cutaneous metastases since initial presentation.

The patient has a history of autoimmune hypothyroidism that predated his melanoma diagnosis, which is well controlled with 50 mg levothyroxine daily. He has no family history of autoimmune disease, vitiligo, or skin cancer.

DISCUSSION

Topical imiquimod is a toll-like receptor 7/8 agonist reported to induce localized vitiligo-like depigmentation months after topical use for condyloma acuminata,³ superficial basal cell carcinoma,⁴ and lentigo maligna.¹ Most prior reports of vitiligo-like depigmentation with imiquimod use note depigmentation localized to the site of application, although regional depigmentation has been

reported after treatment for condyloma acuminata,³ and systemic depigmentation has been reported with combined use of topical monobenzone and imiquimod for cutaneous melanoma metastases.² In the latter report of systemic depigmentation, it was felt the monobenzone provided the systemic effect rather than the imiquimod.²

Given this patient's local and regional depigmentation, in conjunction with resolution of his in-transit melanoma metastases, this case likely represents a regional, rather than a purely local, imiquimod-induced immune response. Interestingly, imiquimod monotherapy has been found to induce a local and a sentinel lymph node regional immune response in melanoma patients, which could explain this patient's regional vitiligo.⁵ Importantly, vitiligo-like depigmentation also may be seen following systemic immunotherapy for melanoma and is associated with improved survival.⁶

Despite leading to resolution of in-transit metastasis, locoregional control with imiquimod may not provide systemic control, evidenced by the development of brain metastasis. Indeed, prior research suggests topical imiquimod for melanoma does not produce a peripheral blood response.⁵ The reason for this finding is unknown but may be owing to different immunologic requirements to treat local versus systemic disease. A murine model of mesothelioma has found that local imiquimod administration induces a local immune response that requires CD8 T cells and natural killer cells, but not CD4 T cells, and is sufficient to retard local, but not distant, tumor growth.⁷ When CD40 antibody, to simulate CD4 T cells, was added to local imiquimod administration, there was distal tumor growth retardation and enhanced local tumor response.⁷

We postulate that similar to immunotherapy-induced vitiligo, a vitiligo-like response to topical imiquimod treatment in melanoma patients may portend a positive locoregional prognosis given the possibility of a regional lymphatic treatment effect, although systemic prognosis remains unaffected. Further studies are needed to confirm this hypothesis.

REFERENCES

1. Kim NH, Lee JB, Yun SJ. Development of Vitiligo-like depigmentation after treatment of lentigo maligna melanoma with 5% imiquimod cream. *Ann Dermatol*. 2018;30(4):454-457.
2. Teulings HE, Tjin EPM, Willemsen KJ, et al. Anti-Melanoma immunity and local regression of cutaneous metastases in melanoma patients treated with monobenzone and imiquimod; a phase 2 a trial. *Oncoimmunology*. 2018;7(4):e1419113.
3. Stefanaki C, Nicolaidou E, Hadjivassiliou M, Antoniou C, Katsambas A. Imiquimod-induced vitiligo in a patient with genital warts [14]. *J Eur Acad Dermatol Venereol*. 2006;20(6):755-756.
4. Burnett CT, Kouba DJ. Imiquimod-induced depigmentation: report of two cases and review of the literature. *Dermatol Surg*. 2012;38(11):1872-1875.
5. Narayan R, Nguyen H, Bentow JJ, et al. Immunomodulation by imiquimod in patients with high-risk primary melanoma. *J Invest Dermatol*. 2012;132(1):163-169.
6. Teulings HE, Limpens J, Jansen SN, et al. Vitiligo-like depigmentation in patients with stage III-IV melanoma receiving immunotherapy and its association with survival: a systematic review and meta-analysis. *J Clin Oncol*. 2015;33(7):773-781.
7. Broomfield SA, van der Most RG, Amy C, et al. Locally administered TLR7 agonists drive systemic antitumor immune responses that are enhanced by anti-CD40 immunotherapy. *J Immunol*. 2009;182(9):5217-5224.