

Oxybutynin treatment for buprenorphine-naloxone-induced hyperhidrosis



Lindsay McCormack, BA,^{a,b,c} Joseph Ponce, BS,^{a,b} Avik Chatterjee, MD, MPH,^{a,d} and Jennifer K. Tan, MD^{a,b,e}
Boston and Worcester, Massachusetts

Key words: buprenorphine-naloxone; hyperhidrosis; opioid agonists; opioid antagonists; opioid use disorder; oxybutynin; suboxone.

INTRODUCTION

Hyperhidrosis occurs when sweating is excessive for thermoregulatory purposes, which may result in decreased quality of life and emotional stress for patients.¹ Classified as primary and secondary, secondary hyperhidrosis is often related to an underlying cause.² Certain medications have been reported to induce hyperhidrosis, including selective serotonin reuptake inhibitors, tricyclic antidepressants, and opioid agonists.²⁻⁴ We present the case of a woman with a history of opioid use disorder who experienced hyperhidrosis in the setting of partial opioid agonist and opioid antagonist therapy (buprenorphine-naloxone), who was treated successfully with oral oxybutynin 5 mg daily.

CASE REPORT

A 28-year-old woman with a history of intranasal heroin and cigarette use presented for treatment of opioid use disorder. She discontinued intranasal heroin and began oral buprenorphine-naloxone 12 mg-3 mg daily. Approximately one month after starting buprenorphine-naloxone, she developed excessive, whole-body sweating that spared the palms and axillae. She had no previous personal or family history of hyperhidrosis or skin disease. Though she had delivered her fourth child by C-section shortly before starting buprenorphine-naloxone treatment, she experienced no pregnancy complications such as gestational diabetes or post-operative infection. She had no history of postpartum hyperhidrosis with her prior three pregnancies. She did not show or endorse any other

symptoms of opioid withdrawal including nausea, vomiting, abdominal pain, joint pain, dilated pupils, watery eyes, insomnia, or tremor. Review of systems and physical exam findings were unremarkable for any symptoms of thyroid disease, diabetes, autonomic disorders, infection, or malignancy. Due to the unremarkable review of systems and being in a limited-resource setting, an extensive endocrine work-up was not performed. While she did have a history of anxiety and depression in the setting of homelessness, these conditions were managed successfully before hyperhidrosis symptoms began, and she did not endorse anxiety when sweating occurred. She continued to smoke half a pack of cigarettes daily before and during buprenorphine-naloxone use.

Because her hyperhidrosis was initially attributed to opioid withdrawal, her dose of buprenorphine-naloxone was increased from 12 mg-3 mg daily to 16 mg-4 mg daily. While hyperhidrosis had initially occurred only during early morning hours, dosage increase resulted in the development of symptoms persisting throughout the day, occurring at rest and with exercise. Her palms and soles were newly involved and with particularly severe manifestations. Dermatology was consulted, and a trial of oral oxybutynin 5 mg daily was recommended, which resulted in cessation of her symptoms. She discontinued oxybutynin for several days due to her prescription lapsing, and her sweating recurred during this time. Symptoms again resolved within one week of restarting oxybutynin.

From the Boston Health Care for the Homeless Program^a; Massachusetts General Hospital, Department of Dermatology^b; University of Massachusetts Medical School^c; Boston University School of Medicine, Department of Internal Medicine^d; and Harvard Medical School.^e

Funding sources: None.

Correspondence to: Jennifer K. Tan, MD, Department of Dermatology, Massachusetts General Hospital, 50 Staniford Street, Suite 200, Boston, MA 02114. E-mail: jt看5@partners.org.

JAAD Case Reports 2021;10:22-4.
2352-5126

© 2021 by the American Academy of Dermatology, Inc. Published by Elsevier, Inc. This is an open access article under the CC BY-NC-ND license (<http://creativecommons.org/licenses/by-nc-nd/4.0/>).

<https://doi.org/10.1016/j.jidcr.2020.12.031>

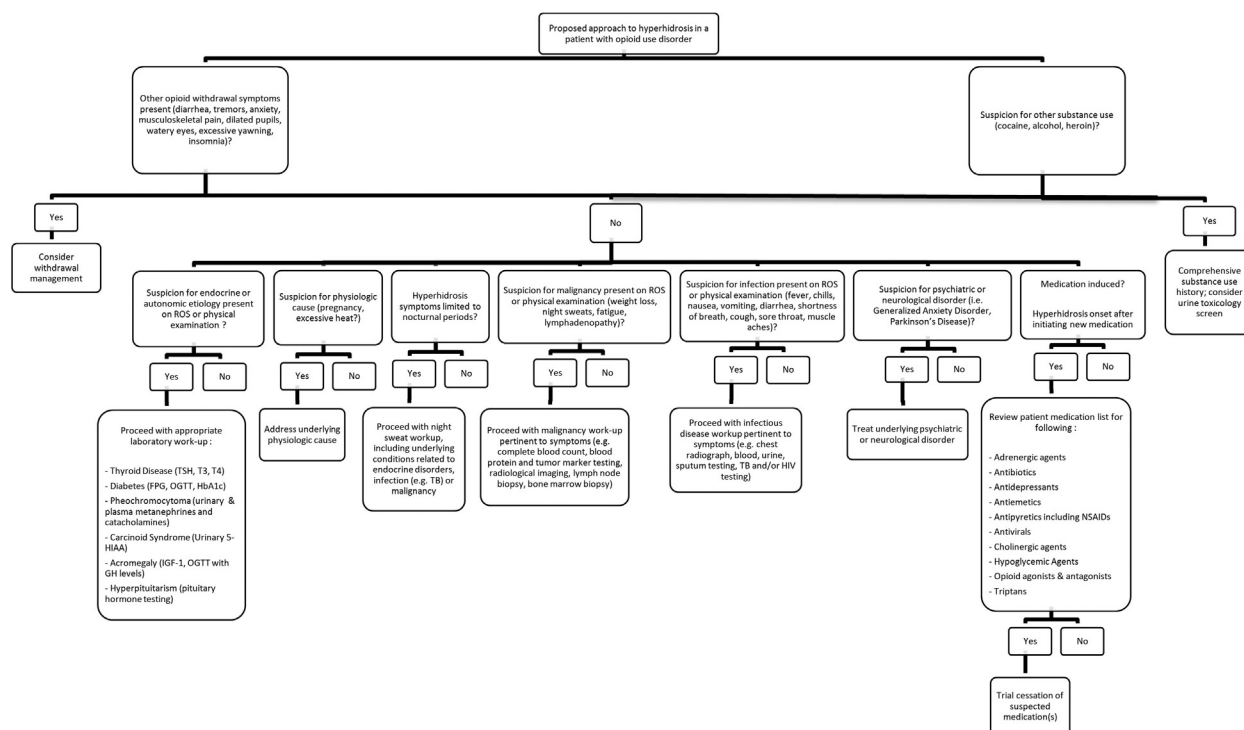


Fig 1. A proposed approach to a patient with hyperhidrosis and opioid use disorder. This approach has been adapted from recommendations provided by Nawrocki et al² and Hong et al.⁴

DISCUSSION

According to recent statistics, 128 people in the United States die from opioid overdose every day.⁵ A new report suggests that caring for patients with opioid use disorder has become even more of an emergency during the Coronavirus Disease 2019 pandemic, as more patients will experience withdrawal in the face of changing drug markets, while those already receiving treatment may struggle to maintain critical access to care.⁶

Treatment for opioid use disorder includes partial opioid agonist and opioid antagonist therapies such as buprenorphine-naloxone. While hyperhidrosis related to opioid agonist therapies has been reported,⁷ literature surrounding potential treatment for buprenorphine-naloxone-induced hyperhidrosis is sparse. Hong et al. reported a case of methadone-induced hyperhidrosis in which a patient receiving methadone maintenance therapy presented with excessive sweating immediately after beginning methadone.⁴ Similar to our patient, he did not experience any other symptoms of withdrawal and his hyperhidrosis also resolved from treatment with oral oxybutynin.⁴

Topical therapies including aluminum chloride and glycopyrronium tosylate are often used as

first-line treatments for hyperhidrosis. However, since our patient's symptoms were widespread, oral oxybutynin was chosen due to its systemic distribution, low levels of adverse side effects,⁸ and efficacy in the treatment of a patient with methadone-induced hyperhidrosis.⁴ Oxybutynin has traditionally been used as an anti-cholinergic medication for the treatment of overactive bladder.⁹ While a recent literature review reported that oxybutynin is an efficient and effective drug for the treatment of primary hyperhidrosis, case reports have also described its effectiveness and safety for the treatment of secondary, medication-induced hyperhidrosis.^{8,9} Additionally, because topical therapies, such as aluminum chloride, were not covered by our patient's public insurance, oxybutynin was both a practical and accessible therapeutic alternative.

A recent report suggests that the pathogenesis of methadone-induced hyperhidrosis may at least partly occur as a result of methadone's impact on muscarinic receptors,⁴ though the effect of buprenorphine-naloxone on muscarinic receptors is not well-known. While methadone is an opioid agonist that has been used since the 1960s to treat opioid use disorders, buprenorphine-naloxone has

been used since the early 2000s and is a combination partial opioid agonist (buprenorphine) and non-selective, short-acting opioid receptor antagonist (naloxone). Methadone has a higher retention treatment rate, whereas buprenorphine-naloxone is believed to have a lower rate of overdose and is now the preferred treatment choice for opioid use disorder in the United States.¹⁰ This case demonstrates that the potential side effect of hyperhidrosis that has been associated with methadone therapy may also impact patients undergoing treatment with buprenorphine-naloxone for an opioid use disorder.

Patients receiving treatment for opioid use disorder may also be at risk for poly-substance use.⁴ As a result, frequent urine toxicology screenings can be useful to rule out hyperhidrosis that may be related to the use or withdrawal of other illicit substances, including amphetamines and cocaine.⁴ It is also important to distinguish between medication-induced hyperhidrosis and hyperhidrosis caused by opioid withdrawal.⁴ In patients presenting with hyperhidrosis in the setting of buprenorphine-naloxone treatment for opioid use disorder, a careful history inquiring about additional symptoms of withdrawal including nausea, vomiting, abdominal pain, joint pain, dilated pupils, watery eyes, insomnia, or tremor, should be completed.⁴ Additionally, other etiologies for new-onset hyperhidrosis should be considered, such as proposed in Fig 1.^{2,4} When a review of systems for underlying endocrinopathies, autonomic disorders, psychiatric disorders, infection, and malignancy is unremarkable and no other symptoms of opioid withdrawal are present, oxybutynin could be considered as a

potential therapy for buprenorphine-naloxone-induced hyperhidrosis.

Conflicts of interest

None declared.

REFERENCES

1. McConaghy JR, Fosselman D. Hyperhidrosis: management options. *Am Fam Physician*. 2018;97(11):729-734.
2. Nawrocki S, Cha J. The etiology, diagnosis, and management of hyperhidrosis: A comprehensive review: Etiology and clinical work-up. *J Am Acad Dermatol*. 2019;81(3):657-666.
3. Cheshire WP, Fealey RD. Drug-induced hyperhidrosis and hypohidrosis: incidence, prevention and management. *Drug Saf*. 2008;31(2):109-126.
4. Hong J, Lee J, Totouom-Tangho H, Dunn NR, Swift RG. Methadone-induced hyperhidrosis treated with oxybutynin. *J Addict Med*. 2017;11(3):237-238.
5. National Institute on Drug Abuse. *Opioid overdose crisis*. Bethesda, MD: National Institute on Drug Abuse; 2020. Accessed March 19, 2020. Available at: <https://www.drugabuse.gov/drugs-abuse/opioids/opioid-overdose-crisis>
6. Green TC, Bratberg J, Finnell DS. Opioid use disorder and the COVID 19 pandemic: a call to sustain regulatory easements and further expand access to treatment. *Subst Abuse*. 2020; 41(2):147-149.
7. Gahr M, Eller J, Cabanis M, et al. Drug safety and adverse drug reaction reporting behavior related to outpatient opioid replacement therapy: results from a survey among physicians. *J Subst Abuse Treat*. 2017;74:7-15.
8. Delort S, Marchi E, Correa MA. Oxybutynin as an alternative treatment for hyperhidrosis. *An Bras Dermatol*. 2017;92(2): 217-220.
9. Prouty ME, Fischer R, Liu D. Glycopyrrolate-induced craniofacial compensatory hyperhidrosis successfully treated with oxybutynin: report of a novel adverse effect and subsequent successful treatment. *Dermatol Online J*. 2016;22(10):13030/qt4wp1g44b.
10. Srivastava A, Kahan M, Nader M. Primary care management of opioid use disorders: abstinence, methadone, or buprenorphine-naloxone? *Can Fam Physician*. 2017;63(3):200-205.