

CASE DESCRIPTION

Case: 24-year-old male with worsening left foot neuropathy following chemotherapy and radiation treatment for sarcoma in the left thigh.

Background: He had previously undergone local resection of a 12cm x 8cm x14.5cm rhabdomyosarcoma in the left vastus lateralis. He was then treated with vincristine for 40 weeks and radiation to the left lateral thigh with a maximum dose of 50.4 Gy. The sciatic nerve was outside the target area and received a lower dose. While undergoing chemotherapy, the patient experienced bilateral dysesthesias in his fingertips and feet. He had no history of neuropathy prior to treatment. After chemotherapy was completed, these symptoms subsided in all extremities except for the left foot, which developed atraumatic plantar flexion and dorsiflexion weakness, great toe extensor and flexor weakness, and decreased sensation in the distal great toe to the metatarsal.

Exam: Sensation was decreased in the left distal great toe to the metatarsal, but was otherwise intact in the lower limbs. Distal pulses were intact. Left extensor hallucis longus strength was 3/5, left extensor digitorum brevis was 3/5, left toe flexion was 3/5, ankle dorsiflexion was 4/5, and ankle plantar flexion was 4+/5. Strength was otherwise intact in the lower limbs.

Neuro Diagnostics: Electromyography and needle conduction studies demonstrated left worse than right polyneuropathy mainly affecting the tibial and peroneal motor nerves. There was no clear evidence of a single nerve compressive lesion. (Figure 1)

Imaging: Repeat scans of the left thigh showed no new lesion. (Figure 2)

Motor Summary Table

| Site | NR | Onset (ms) | O-P Amp (mV) | Full Area (mV·ms) | Site1 | Site2 | Delta-0 (ms) | Dist (cm) | Vel (m/s) |
|---|----|------------|--------------|-------------------|------------|-----------|--------------|-----------|-----------|
| Left Peroneal Motor (Ext Dig Brev) 29.8°C | | | | | | | | | |
| Ankle | | 6.6 | 0.4 | 1.82 | B Fib | Ankle | 10.9 | 33.0 | 30 |
| B Fib | | 17.5 | 0.3 | 1.50 | A Fib | B Fib | 1.5 | 10.0 | 67 |
| A Fib | | 19.0 | 0.3 | 1.43 | | | | | |
| Right Peroneal Motor (Ext Dig Brev) 29.8°C | | | | | | | | | |
| Ankle | | 5.2 | 1.0 | 3.41 | B Fib | Ankle | 9.3 | 37.0 | 40 |
| B Fib | | 14.5 | 0.8 | 2.82 | A Fib | B Fib | 1.3 | 0.0 | |
| A Fib | | 15.8 | 0.9 | 3.67 | | | | | |
| Left Peroneal TA Motor (Tib Ant) 25.9°C | | | | | | | | | |
| BFib Head | | 4.1 | 1.9 | 16.48 | A Fib Head | BFib Head | 3.2 | 10.0 | 31 |
| A Fib Head | | 7.3 | 1.0 | 4.38 | | | | | |
| Right Peroneal TA Motor (Tib Ant) 27.8°C | | | | | | | | | |
| BFib Head | | 3.6 | 3.0 | 13.38 | A Fib Head | BFib Head | 1.8 | 10.0 | 56 |
| A Fib Head | | 5.4 | 2.8 | 12.92 | | | | | |
| Left Tibial Motor (Abd Hallucis) 25.9°C | | | | | | | | | |
| Ankle | | 5.5 | 0.9 | 5.46 | Knee | Ankle | 6.7 | 39.0 | 58 |
| Knee | | 12.2 | 0.0 | 0.42 | | | | | |
| Right Tibial Motor (Abd Hallucis) 29.2°C | | | | | | | | | |
| Ankle | | 6.1 | 7.9 | 39.35 | Knee | Ankle | 9.8 | 40.0 | 41 |
| Knee | | 15.9 | 6.6 | 14.96 | | | | | |

EMG

| Side | Muscle | Nerve | Root | Fibs | Psw | Amp | Dur | Poly | Recrt | Effort | CRD | Other | Comment |
|------|---------------|--------------|------|------|-----|------|-------|------|------------------|--------|-----|-------|---------|
| Left | Ant Tibialis | Dp Br Peron | Nml | 0 | 1+ | Incr | Nml | 0 | Reduced | Nml | 0 | | |
| Left | Peroneus Long | Sup Br Peron | Nml | 0 | 1+ | Incr | >12ms | few | Slightly Reduced | Nml | 0 | | |
| Left | MedGastroc | Tibial | Nml | 0 | 1+ | Incr | >12ms | few | Slightly Reduced | Nml | 0 | | |
| Left | VastusMed | Femoral | Nml | 0 | 2+ | Nml | >12ms | many | Slightly Reduced | Nml | 0 | | |
| Left | BicepsFemS | Sciatic | Nml | 0 | 0 | Incr | Nml | 0 | Slightly Reduced | Nml | 0 | | |
| Left | GluteusMed | SupGluteal | Nml | 0 | 0 | Nml | Nml | 0 | Nml | Nml | 0 | | |

Figure 1: Motor nerve conduction and EMG studies

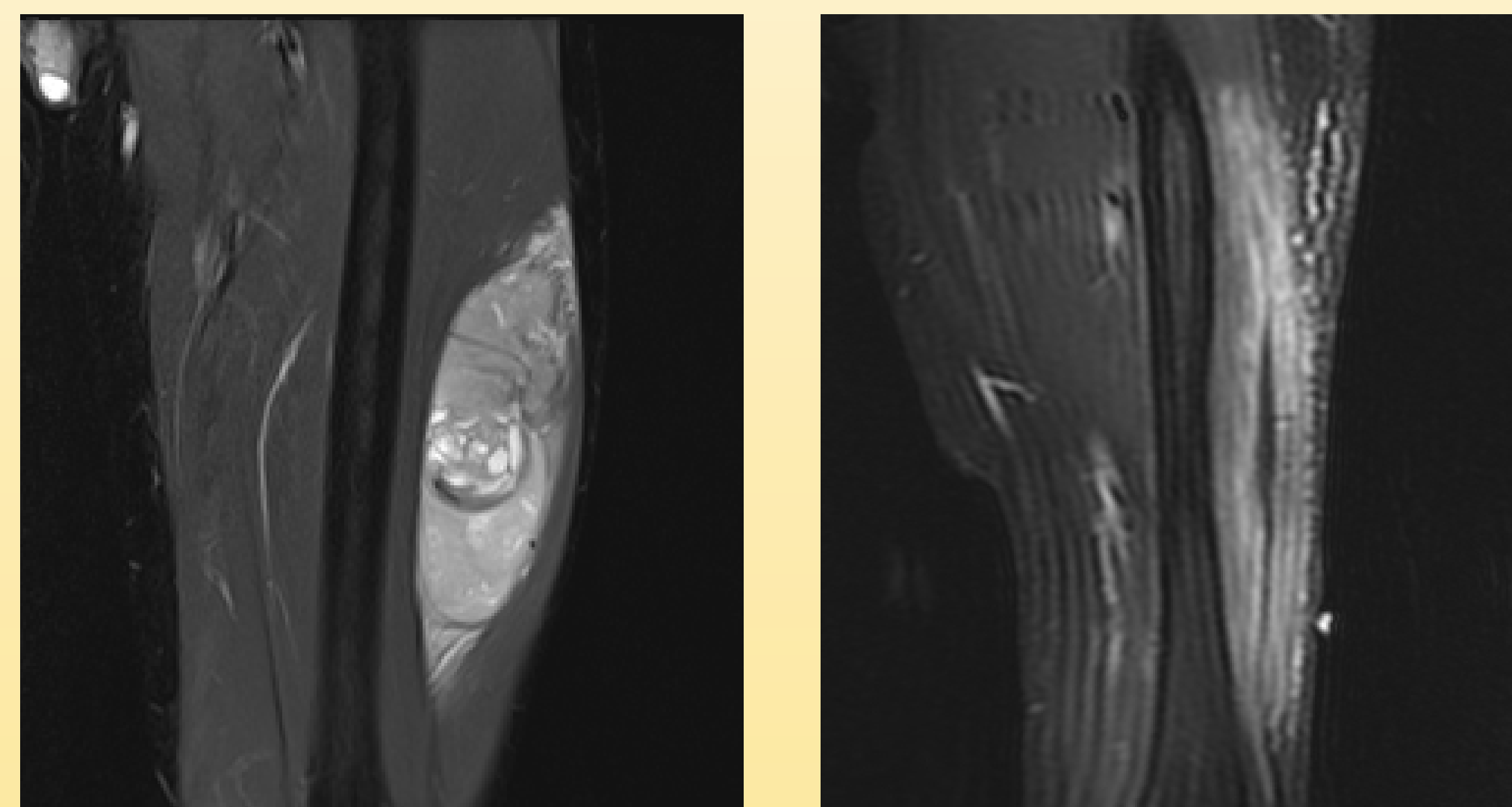


Figure 2: MRI with of left thigh prior to surgical resection (left) and repeat MRI (right) at time of onset of neuropathy symptoms one year post-op.

References

- Seretny, M et al. Incidence, prevalence, and predictors of chemotherapy-induced peripheral neuropathy: a systematic review and meta-analysis. *PAIN*. 2014 Dec 31;155(12):2461-70.
- Stubblefield, M. Radiation Fibrosis Syndrome: Neuromuscular and Musculoskeletal Complications in Cancer Survivors. *PM&R*. 2011;3:1041-54.

DISCUSSION

Given the presence of milder nerve abnormalities of the right lower limb in addition to the patient's left sided lower limb weakness, the cause is likely multifactorial and temporally related to his cancer treatments.

Persistent or worsening neuropathy features may appear in patients who received vincristine despite termination of treatment. A review by Seretny et. al. found that 68.1% of patients experience chemotherapy induced peripheral neuropathy one month after chemotherapy, and 30% continue to experience neuropathy six or more months after treatment. The pattern of CIPN is typically predominantly a sensory neuropathy, but may be accompanied by motor changes, as seen in this patient, or even autonomic features.

The left worse than right pattern could suggest radiation induced neuropathy, but no myokymic potentials were seen. Myokymic potentials are common in radiation induced neuropathy, although their absence does not rule this out.

Management: Treatment included physical therapy, gabapentin, and an ankle foot orthosis.

Outcome: Fourteen months after completing radiation and seven months after completing chemotherapy, the patient's symptoms are markedly improved.

CONCLUSIONS

Neuropathy after treatment in sarcoma patients may be multifactorial. Imaging may be necessary to rule out recurrence. Establishing both the chronology of complaints and cancer treatments is important to determine the most likely etiology.