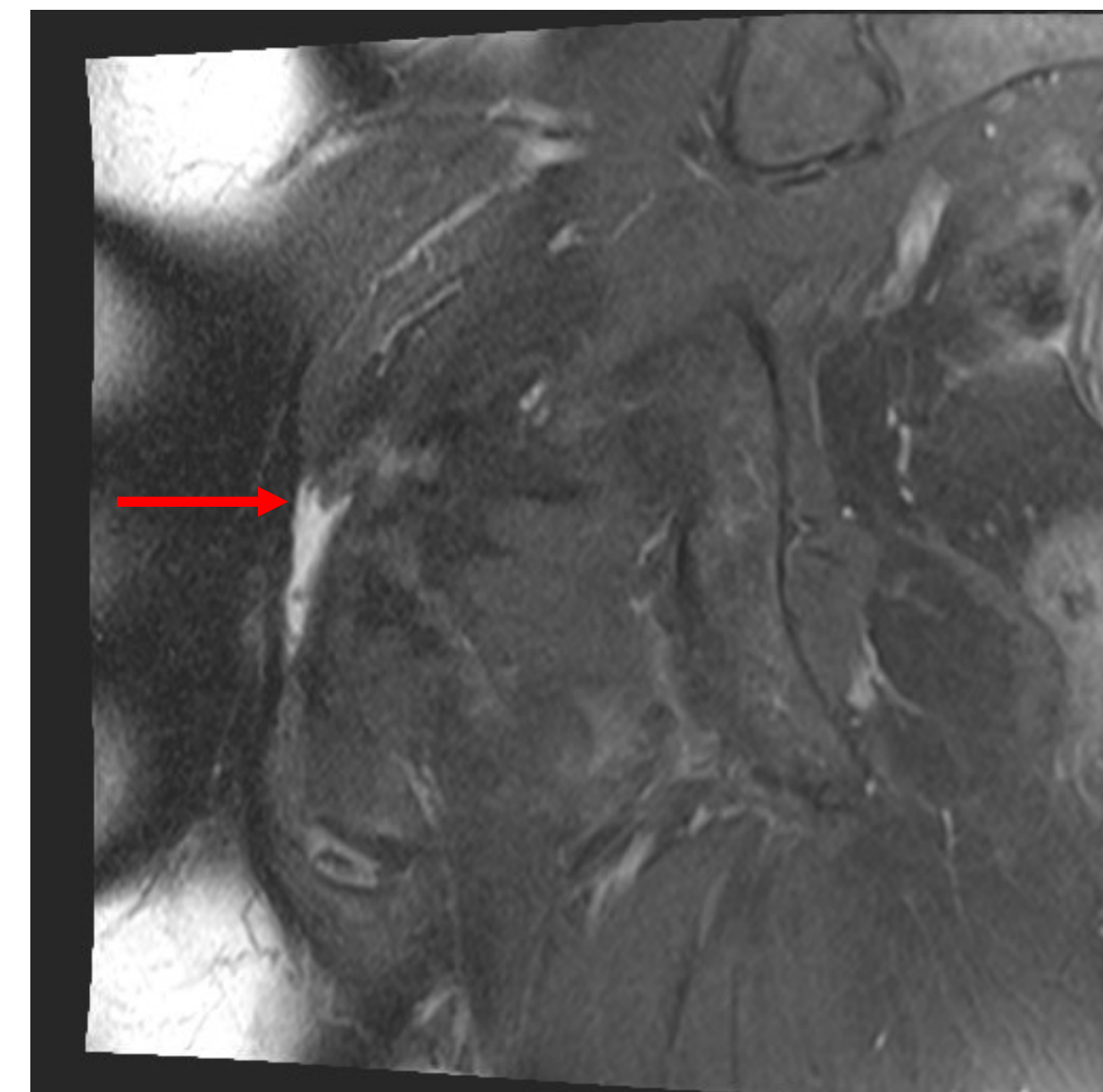


Case One

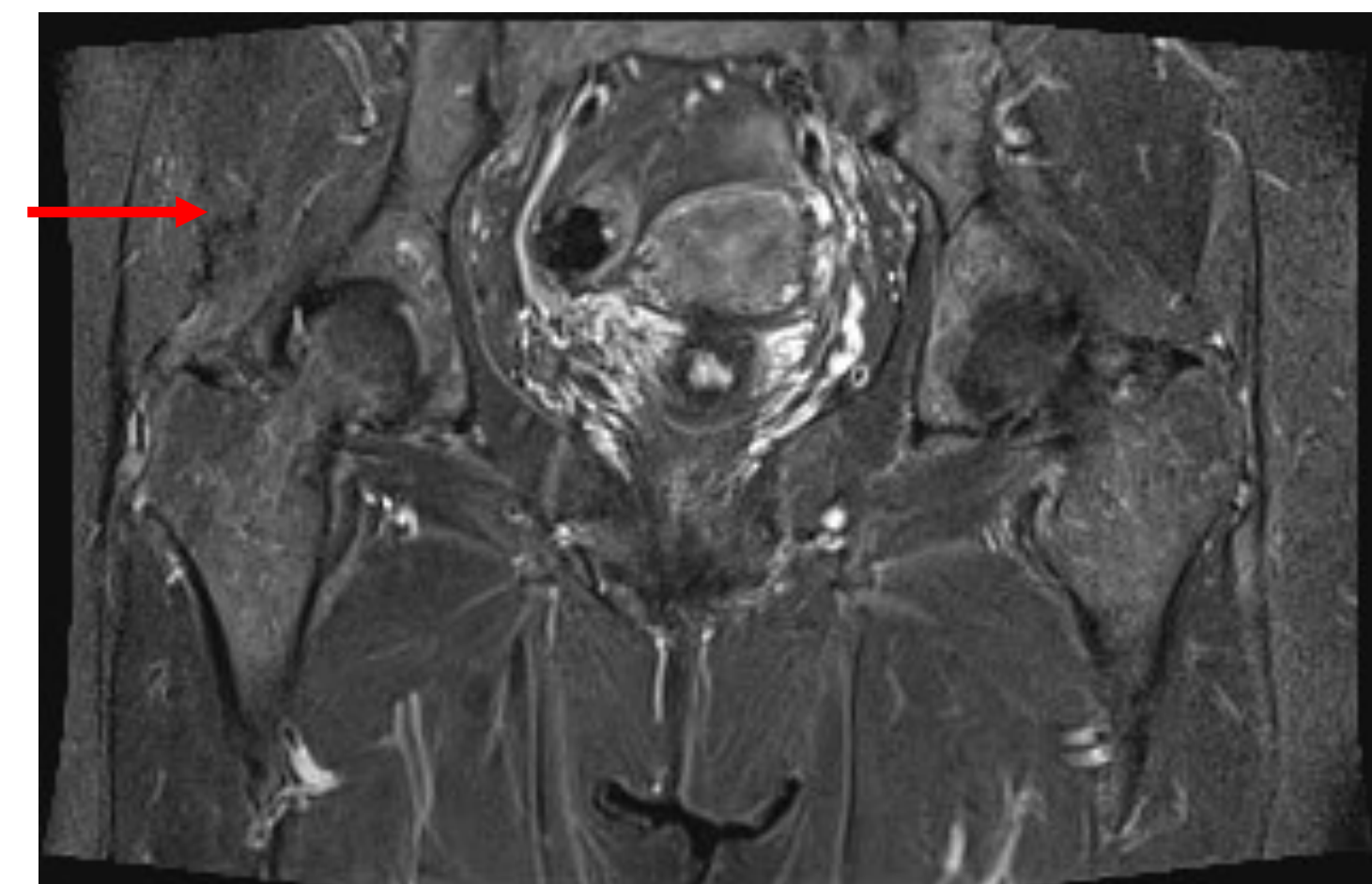
- ❖ 58 year-old female presenting with right hip and gluteal pain.
- ❖ The pain radiates out laterally from the gluteal region but does not spread down the leg.
- ❖ Worse with activity, but not better with rest.
- ❖ No accompanying back pain.
- ❖ Hard to turn her hip out and to walk for a prolonged period of time.
- ❖ Sedentary lifestyle.
- ❖ Did not have fluoroquinolone or steroid exposure near the time of tear.

- ❖ Physical Exam
 - BMI 32
 - Sensation is intact to pinprick.
 - Patellar reflexes are 2+, Achilles reflexes are trace.
 - Focal tenderness in the right gluteal area with pain on external rotation of the right hip.
 - Antalgic gait.

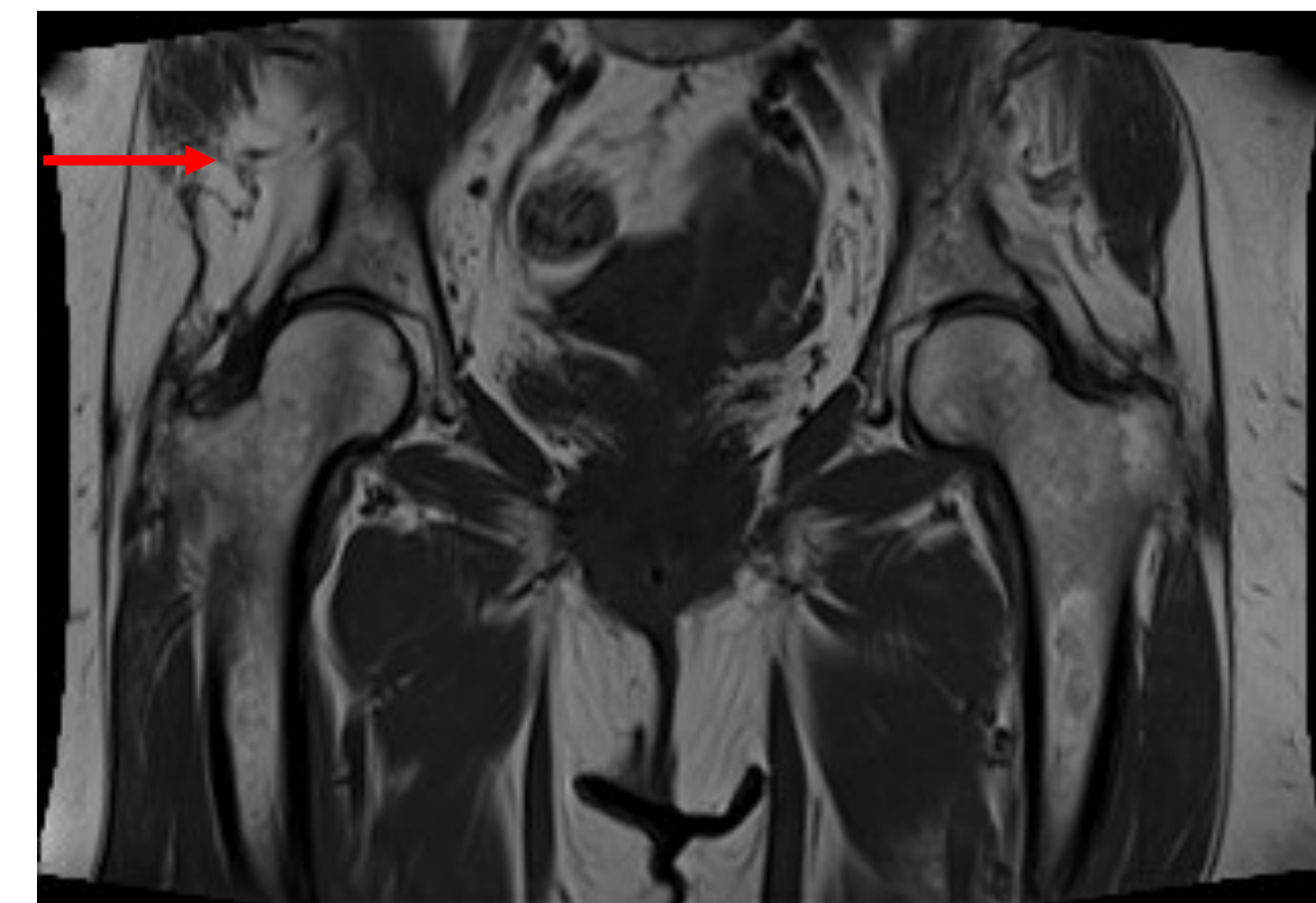
- ❖ Imaging
 - Complex tear of the anterior and anterior superior right acetabular labrum.
 - Moderate bilateral gluteus minimus and medius fatty atrophy.
 - Near complete tear of the right gluteus medius tendon with moderate insertional tendinosis of the right gluteus minimus.



View: coronal PD fat sat



View: coronal STIR



View: coronal T1

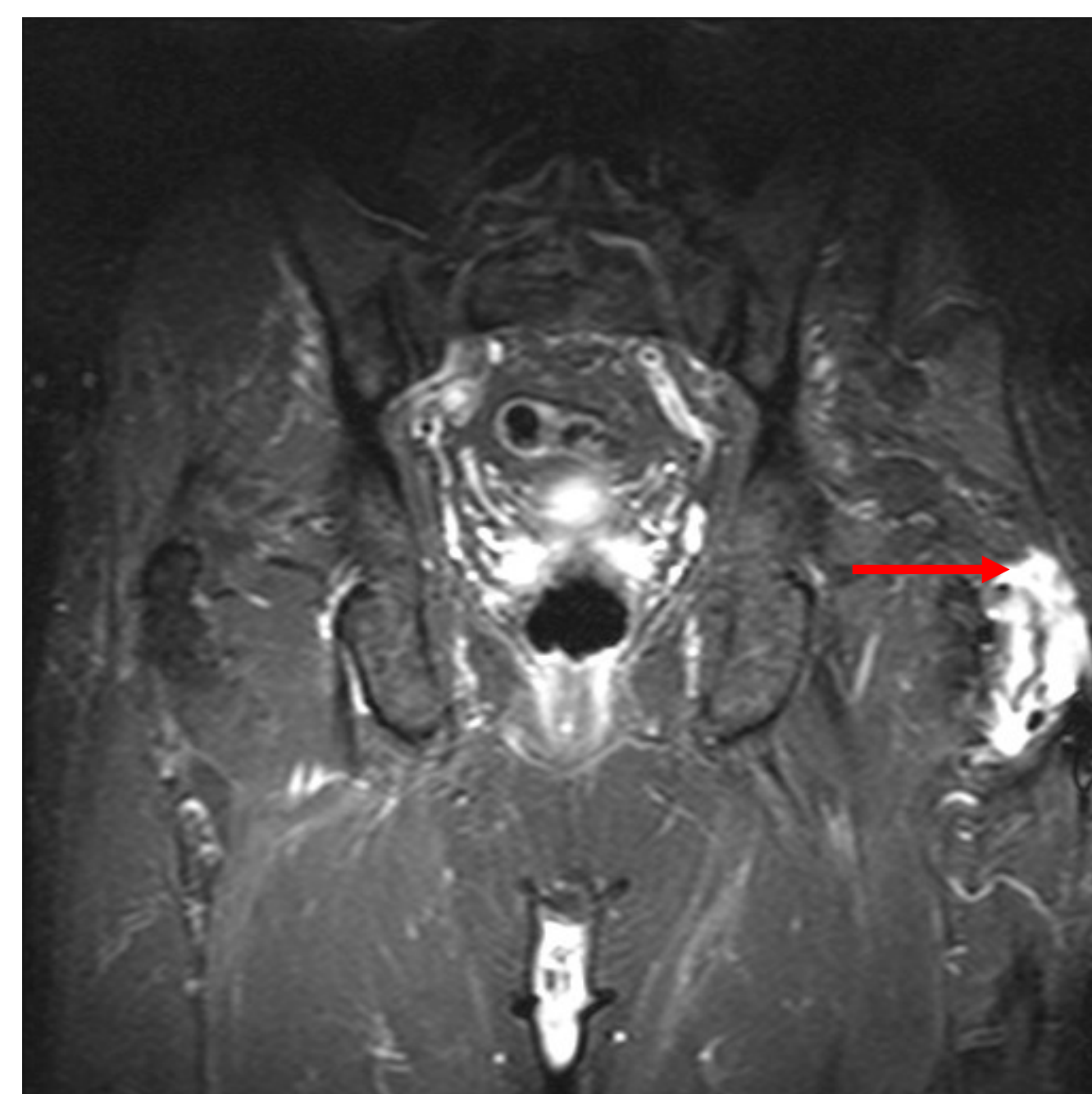
Figure 1. MRI demonstrating gluteus medius tear for patient in Case One.

Case Two

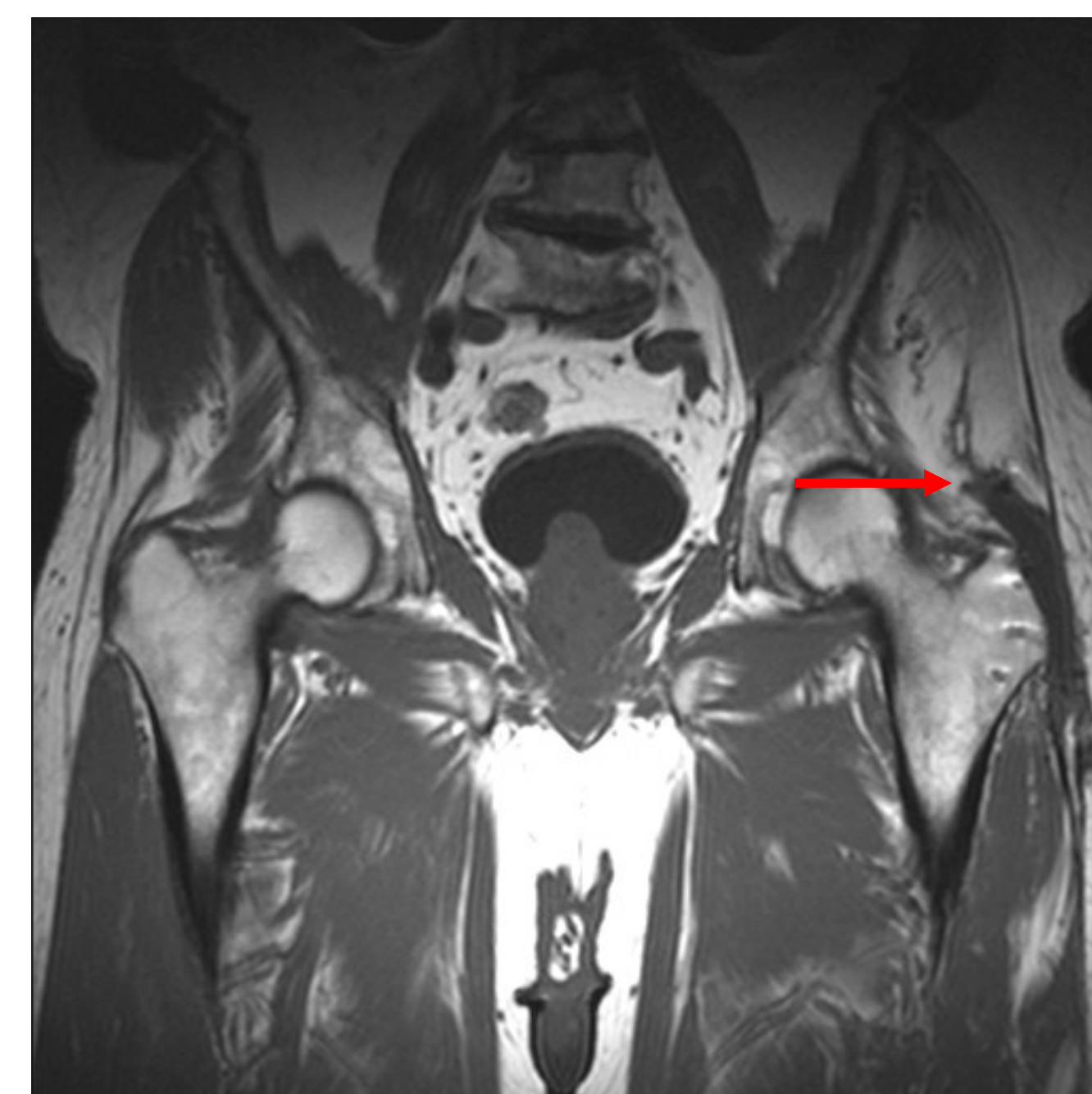- ❖ 82 year-old male status post left gluteus medius repair with subsequent revision presents with chronic left hip pain.
- ❖ A few years ago, a torn tendon was repaired with surgery, followed by revision surgery. Pain was not alleviated.
- ❖ Sedentary lifestyle.
- ❖ Did not have fluoroquinolone or steroid exposure near the time of tear.

- ❖ Physical Exam
 - No atrophy of the trunk and lower limbs on inspection.
 - Strength of the lower limbs is normal and symmetric throughout, however, left hip abduction is limited.
 - Tenderness over the iliopsoas muscle.
 - Good ROM of left hip, knee and ankle.
 - No tenderness over the greater trochanteric bursa bilaterally.

- ❖ Imaging
 - Tear of the majority of the repaired gluteus medius tendon attachment to the left greater trochanter with a tiny portion of the tendon remaining attached at the far posterior medial aspect of the greater trochanter.
 - The repaired gluteus minimus tendon has increased signal with possible partial tear at the anterior insertion on the greater trochanter.



View: coronal STIR



View: coronal T1

Figure 2. MRI demonstrating gluteus medius tear for patient in Case Two.

*The MRIs for Case Two represent an earlier MRI that only shows the previous tear.

Treatment

Both patients were advised to begin physical therapy, take anti-inflammatories as needed, and could receive steroid injections if physical therapy (PT) did not help.

Outcome

Case One

- Decreased pain from 9/10 to 6/10 after PT.
- In subsequent follow up, patient received greater trochanteric bursa injection with further pain relief.

Case Two

- Decreased pain level from 8/10 to 6/10 after PT.
- Able to increase his walking from 70 minutes to 100-150 minutes.
- L hip ROM improved, abduction increased from 20° to 50°.
- Improved strength in lower limbs.

Discussion

Chronic gluteus medius tears may be seen more frequently in those with decreased flexibility or strength. Greater trochanteric pain from bursitis or tendon pathology is estimated at 1.8 patients per 1,000 per year. This is more common in women, and patients with arthritis, low back pain, iliotibial band tenderness, and obesity. Neither patient had medication risk factors for muscle tear, but both endorsed a sedentary lifestyle and one was obese with hip arthritis. These tears can be treated successfully nonoperatively or with surgery. Nonoperative management includes pain control and physical therapy to target the hip rotators. Conservative treatment will provide most patients with pain relief. However, few studies have evaluated the best exercises for the management of gluteus medius tears. Exercise can improve patient function without the risks associated with surgery.

Conclusion

This case series suggests that atraumatic gluteus medius tendon tears may be effectively treated nonoperatively, especially for patients with a sedentary lifestyle. Further studies should be conducted to evaluate the role of nonoperative treatment.

References

- Chandrasekaran, S., Vemula, S. P., Gui, C., Suarez-Ahedo, C., Lodhia, P., & Domb, B. G. (2015). Clinical Features That Predict the Need for Operative Intervention in Gluteus Medius Tears. *Orthop J Sports Med*, 3(2), 2325967115571079.
- Chi, A. S., Long, S. S., Zoga, A. C., Read, P. J., Deely, D. M., Parker, L., & Morrison, W. B. (2015). Prevalence and pattern of gluteus medius and minimus tendon pathology and muscle atrophy in older individuals using MRI. *Skeletal Radiol*, 44(12), 1727-1733.
- Kingzett-Taylor, A., Tirman, P. F., Feller, J., McGann, W., Prieto, V., Wischer, T., Genant, H. K. (1999). Tendinosis and tears of gluteus medius and minimus muscles as a cause of hip pain: MR imaging findings. *AJR Am J Roentgenol*.
- Williams, B. S., & Cohen, S. P. (2009). Greater trochanteric pain syndrome: a review of anatomy, diagnosis and treatment. *Anesth Analg*, 108(5), 1662-1670.