

# ThinPrep Cytopathology of a Cutaneous Meningioma with Histologic Correlation



**Ahmed M. Alhusseiny, MD & Rukmini M. Kashikar, MD**  
Pathology Department, Baystate Medical Center, University of Massachusetts, Springfield, MA

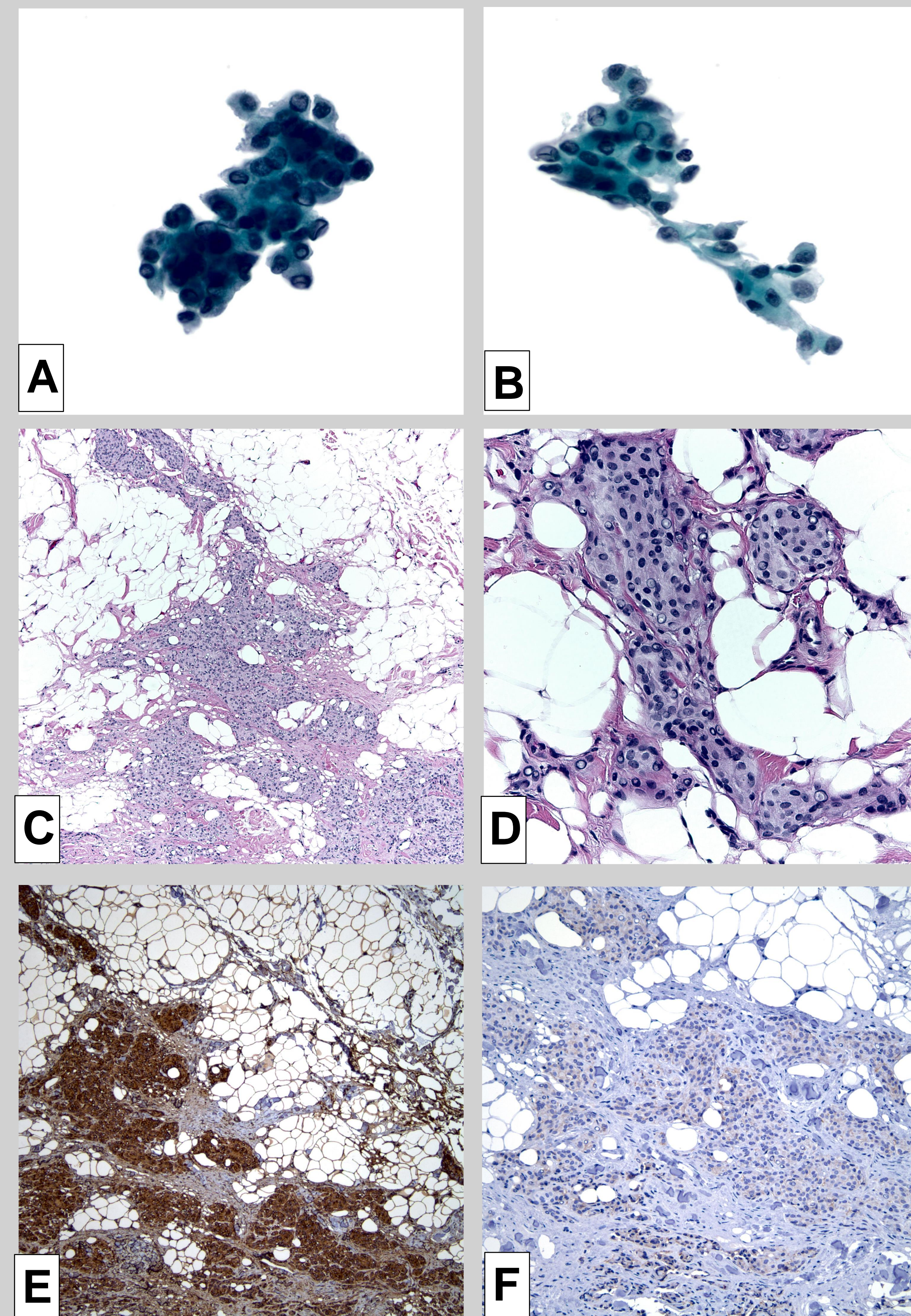


## Introduction

Cutaneous (extracranial) meningioma is a rare entity with an incidence of 1-2% of all meningiomas. These tumors can be ectopic or metastatic and commonly present as firm, painless subcutaneous nodules on the scalp and along the vertebral axis. Due to the non-specific presentation of this tumor, a wide clinical differential diagnosis is considered, which poses a diagnostic challenge and requires tissue microscopy for a definitive diagnosis.<sup>[1,2]</sup> Only a few cases of cutaneous meningioma with the cytologic features have been reported in the literature and most are based on conventional smears. In this report, we present a case of ectopic meningioma with the cytomorphologic features that were evaluated on a ThinPrep (TP) liquid based preparation as well as the subsequent histological correlation.

## Case Presentation

A 59-year-old male with a past medical history of chronic rhinitis presented with an asymptomatic, slowly enlarging mass on the left forehead. On palpation, a firm, deep subcutaneous mass measuring 2.5 cm was noted. On imaging, a lipoma was diagnosed without underlying calvarial abnormality or intracranial mass extension. Fine needle aspiration of the lesion was performed revealing a hypocellular tumor composed of polygonal cells arranged in small clusters and single cells. The cells showed moderate amount of cytoplasm and bland appearing oval nuclei with intranuclear grooves and pseudo-inclusions. A final diagnosis of epithelioid neoplasm favoring an extracranial meningioma was rendered. Due to the hypocellularity and lack of cell block material for immunocytochemistry to further characterize the neoplastic cells, a tissue biopsy was recommended for a definitive diagnosis. On histological evaluation, the excisional biopsy showed a subcutaneous neoplasm consisting of cells in nests and whorls. The tumor cells were round to oval with pale cytoplasm, indistinct cell borders, and intranuclear cytoplasmic pseudo-inclusions (H&E, 40x). {E} Vimentin shows diffuse and strong staining and {F} EMA shows focal staining.



**Figure.** {A,B} Cytology shows polygonal cells in clusters with moderate cytoplasm and bland appearing nuclei with intranuclear grooves and pseudoinclusions (ThinPrep Pap, 40x). {C} The tumor cells are arranged in nests in the subcutaneous tissue (H&E, 10x). {D} The cells were round to oval with pale cytoplasm, indistinct cell borders, and intranuclear cytoplasmic pseudo-inclusions (H&E, 40x). {E} Vimentin shows diffuse and strong staining and {F} EMA shows focal staining.

## Discussion

Cutaneous (extracranial) meningioma is a rare neoplasm and is hypothesized to arise from ectopic arachnoid lining cells. These tumors are divided into 3 types based on their pathogenesis.

Type 1 extracranial meningioma is a congenital variant arising in the scalp, forehead and paravertebral areas and is believed to occur due to abnormalities in the neural tube closure and relocation of meningeal tissue in the surrounding skin and subcutis. It can be clinically misdiagnosed as a skin tag, nevus, epidermal inclusion cyst or a lipoma.

Type 2 tumor can occur at any age and tends to arise in the vicinity of sensory organs (eye, ear, and nose) and along the paths of cranial and sensory nerves. It is hypothesized to arise from remnants of arachnoid cells extending along the nerves<sup>[3]</sup>.

Type 3 cutaneous meningioma is an extension of a primary intracranial meningioma into the dermis or subcutis and some authors in the literature do not consider it as a true extracranial meningioma<sup>[3,4]</sup>.

Given the rarity of this neoplasm and its occurrence in unusual locations, a cytopathologist may not be familiar with its cytomorphology. In addition, most cases in the literature reported cytologic features of cutaneous meningioma based on conventional smears. Our case, on the other hand, is based on TP cytology. Although, the differential diagnosis on TP can range from reactive lesions (e.g. granuloma, fasciitis) to neoplastic mesenchymal tumors (e.g. neural tumors, myoepithelioma, follicular dendritic tumor), the readily identifiable features of the neoplasm clinches the diagnosis. In addition, immunocytochemistry can be helpful if a cell block is available.

## Conclusion

Cutaneous meningioma is rarely encountered in cytologic specimens and may pose a diagnostic challenge to a cytopathologist as they may be unfamiliar with this entity. In addition, this lesion can be confused with other tumors, especially when tumors demonstrate atypia and unusual cytomorphologic features. Awareness of the cytomorphologic features of this uncommon entity will diminish the risk of misdiagnosis.

## References

1. Ocque. R et al., Cytopathology of extracranial ectopic and metastatic meningioma. Acta Cytologica, 2013
2. J. R. Miedema and D.I Zedek. Cutaneous meningioma. Arch Pathol Lab Med, 2012
3. J. Goldblum, A. Folpe and S. Weiss. Enzinger's and Weiss's soft tissue tumors, 6<sup>th</sup> edition. 2014
4. Lopez. DA et.al., Cutaneous meningiomas - A clinicopathologic study. Cancer, 1974.