

# Vitiligo of the arm after COVID-19 vaccination



Rhea Singh, BS,<sup>a,b</sup> Jay L. Cohen, MD,<sup>c</sup> Michael Astudillo, MD,<sup>d</sup> John E. Harris, MD, PhD,<sup>e</sup> and Esther E. Freeman, MD, PhD<sup>a,f</sup>

**Key words:** COVID-19; depigmentation; SARS-CoV-2; vaccines; vitiligo.

## INTRODUCTION

As we head into the third year of the COVID-19 pandemic and second year of COVID-19 vaccine availability, cutaneous reactions to COVID-19 and various COVID-19 vaccine types have become increasingly reported and categorized.<sup>1</sup> The American Academy of Dermatology and International League of Dermatological Societies have collaborated to create a COVID-19 dermatology registry to record cases of cutaneous reactions associated with either the infection or the vaccine. The most common cutaneous reactions seen after COVID-19 vaccination are local injection site reactions. There have been limited reports of vitiligo after COVID-19 vaccination to date, and literature remains scarce.<sup>2,3</sup> Clinical trials of COVID-19 vaccines did not report any cases of new-onset vitiligo after mRNA vaccines; however, there was 1 case after adenovirus-based AstraZeneca vaccination among the cutaneous adverse events noted after vaccination.<sup>4</sup> Here, we present a case of a patient developing vitiligo specifically on the arm at the site of injection after COVID-19 vaccination.

## CASE REPORT

A 43-year-old female with Fitzpatrick skin type VI, Hashimoto's thyroiditis, type II diabetes, and psoriasis (previously treated with Humira, currently on topical therapies) presented to the clinic with new-onset change in color of her left arm after receiving

COVID-19 vaccination. The patient noted focal skin depigmentation starting 3 weeks after receiving the first dose of the Moderna mRNA-1273 COVID-19 vaccine, primarily on her left upper arm at the location of the injection site. She subsequently noted a few additional areas of depigmentation on her face, scalp, and chest. There was no symmetric depigmentation of her right (unvaccinated) arm. She denied previous depigmentation of her skin prior to these episodes. Additionally, she had a psoriasis flare-up on her hands and arms bilaterally 1 week after receiving her first vaccine. She had no other symptoms after the first and second doses of the Moderna COVID-19 vaccine. The patient was initiated on betamethasone dipropionate treatment at an outside clinic prior to her visit.

On physical examination, depigmentation of the left upper arm was striking, with noted involvement over the deltoid at the site of vaccination (Fig 1). Perifollicular macules consistent with repigmentation were present within the lesion. Smaller, less prominent, patchy areas of depigmentation were present on the face, scalp, and upper central chest (Fig 2).

Punch biopsy of the left upper arm, from the center of a depigmented area, revealed reduced basal layer melanocytes and irregular epidermal pigmentation. A Fontana-Masson stain highlighted heterogeneous melanin pigment within the epidermis, with foci of markedly reduced pigment.

From the Department of Dermatology, Massachusetts General Hospital, Harvard Medical School, Boston, Massachusetts<sup>a</sup>; Virginia Commonwealth University School of Medicine, Richmond, Virginia<sup>b</sup>; Department of Dermatology, Newton-Well-esley Hospital, Newton, Massachusetts<sup>c</sup>; Department of Pathology, Massachusetts General Hospital, Harvard Medical School, Boston, Massachusetts<sup>d</sup>; Department of Dermatology, University of Massachusetts Chan Medical School, Worcester, Massachusetts<sup>e</sup>; Medical Practice Evaluation Center, Mongan Institute, Massachusetts General Hospital, Boston, Massachusetts.<sup>f</sup>

Funding sources: None.

IRB approval status: Not applicable.

Consent: Consent for the publication of patient photographs and medical information was provided by the authors at the time of

article submission to the journal stating that patient gave consent for their photographs and medical information to be published in print and online and with the understanding that this information may be publicly available.

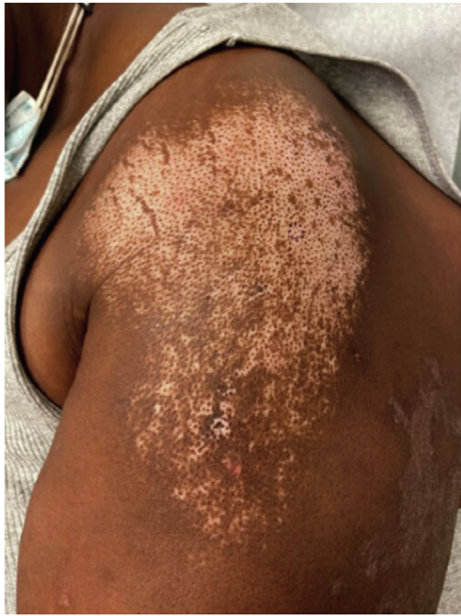Correspondence to: Esther E. Freeman, MD, PhD, Department of Dermatology, Massachusetts General Hospital, 50 Staniford St, Boston, MA 02114. E-mail: [efreeman@mgh.harvard.edu](mailto:efreeman@mgh.harvard.edu).

JAAD Case Reports 2022;28:142-4.

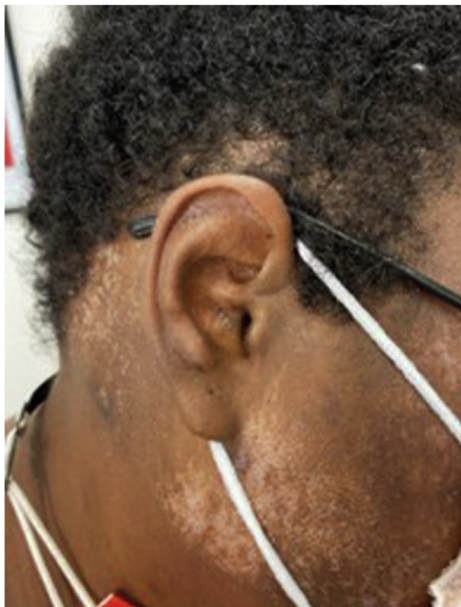2352-5126

© 2022 Published by Elsevier on behalf of the American Academy of Dermatology, Inc. This is an open access article under the CC BY-NC-ND license (<http://creativecommons.org/licenses/by-nc-nd/4.0/>).

<https://doi.org/10.1016/j.jidcr.2022.06.003>

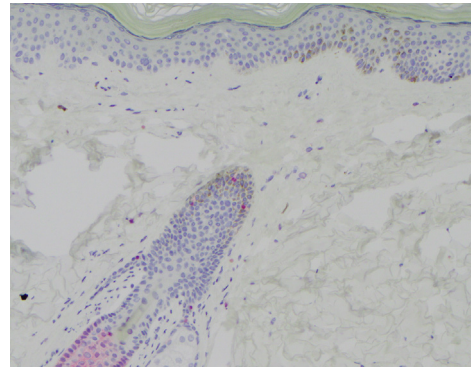


**Fig 1.** Depigmentation and repigmentation of the *left* arm at the site of vaccine administration.

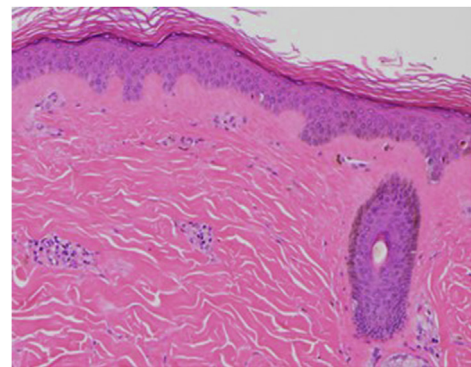


**Fig 2.** Depigmentation and repigmentation of the face.

A Microphthalmia transcription factor immunohistochemical stain indicated rare junctional epidermal melanocytes, focally overlying hair follicles, with reduced or absent melanocytes in the interfollicular epidermis (Fig 3). The remaining retained pigment and melanocytes were centered around the follicle and adnexal structures. Additionally, there were dyskeratotic keratinocytes in the epidermis (Fig 4).



**Fig 3.** Microphthalmia transcription factor stain of a hair follicle.



**Fig 4.** H&E stain showing dyskeratosis. *H&E*, Hematoxylin and eosin.

These findings are consistent with vitiligo. Laboratory data were significant for an elevated thyroid-stimulating hormone of 5.16 uIU/mL. Complete blood count and basic metabolic panel were within normal limits. The patient was instructed to continue use of betamethasone dipropionate for 1 week and then transition to topical tacrolimus.

## DISCUSSION

This case demonstrates a presentation of vitiligo likely triggered by the COVID-19 vaccine, prominently located at the site of vaccine injection. While literature about vitiligo and COVID-19 vaccination is scarce, a patient with ulcerative colitis was noted to have developed vitiligo on the face after COVID-19 vaccination.<sup>5</sup> Notably, the 2 cases of vitiligo that have been presented to date do not report vitiligo at the area of vaccine administration.<sup>2,3</sup> Since the majority of Americans received the COVID-19 vaccine and vitiligo is relatively common (1% to 2% prevalence),<sup>5</sup> it would not be surprising to see patients reporting vitiligo onset after vaccination, even by chance alone. While it may be difficult to establish an association between vaccination and development

of vitiligo in a patient with pre-existing autoimmune disease, it is suggestive that the depigmentation developed most prominently at the vaccination site.

The mechanism for vaccine-induced vitiligo needs further elucidation, but 1 possible hypothesis is that either local trauma from the vaccination itself or a robust immune response to COVID-19 vaccine helped to promote an autoimmune response targeting melanocytes.<sup>6</sup> A few cases of vitiligo have been reported at the injection site after subcutaneous interferon alpha (IFN- $\alpha$ ) therapy administration in patients receiving treatment for chronic hepatitis C.<sup>7</sup> It is common to see the development of vitiligo at sites of skin trauma through the Koebner phenomenon,<sup>8</sup> and others have noted vitiligo following topical application of imiquimod,<sup>9</sup> which both stimulate production of type I IFNs like IFN- $\alpha$ . The suggested mechanism of action in these patients is still not fully understood; however, vitiligo is driven by interferon gamma (IFN- $\gamma$ ),<sup>10</sup> a type II IFN that induces similar signaling responses as type I IFNs like IFN- $\alpha$ . Thus, type I IFNs, such as IFN- $\alpha$ , may induce inflammation that drives autoimmunity in vitiligo through a feed-forward mechanism initiated by type I IFN and then propagated through type II IFN.<sup>5</sup> Because type I IFNs are produced following COVID-19 vaccination, the vaccine itself may follow a similar pattern to the other phenomena, resulting in local inflammation and attracting autoimmune T cells to initiate depigmentation at the vaccination site.

Another possible cause of this patient's presentation that may act in conjunction with the previous hypothesis is the Koebner phenomenon, defined as the formation of skin lesions, after secondary trauma, on parts of the body where a person does not typically experience lesions.<sup>6</sup> This patient may be exhibiting koebnerization via the COVID-19 vaccine acting as an insult or source of secondary trauma, initiating the cascade of events leading to melanocyte destruction and depigmentation. The removal of the insult initiates uncharacteristically fast repigmentation around the hair follicles (within months) as seen in this patient. If repigmentation occurs in people with vitiligo, it generally takes months to years. We cannot rule out the possibility that her

Hashimoto's thyroiditis and/or psoriasis also predisposed her to develop new-onset vitiligo. However, it is particularly notable that the area of insult was the most significantly affected by depigmentation in this patient.

Further research into the mechanism of action of depigmentation would be helpful if there are increasing reports of vitiligo or new-onset cutaneous autoimmune reactions after COVID-19 vaccination.

#### Conflicts of interest

None disclosed.

#### REFERENCES

1. McMahon DE, Amerson E, Rosenbach M, et al. Cutaneous reactions reported after Moderna and Pfizer COVID-19 vaccination: a registry-based study of 414 cases. *J Am Acad Dermatol*. 2021;85(1):46-55. <https://doi.org/10.1016/j.jaad.2021.03.092>
2. Ciccarese G, Drago F, Boldrin S, et al. Sudden onset of vitiligo after COVID-19 vaccine. *Dermatol Ther*. 2022;35(1):e15196. <https://doi.org/10.1111/dth.15196>
3. Aktas H, Ertuğrul G. Vitiligo in a COVID-19-vaccinated patient with ulcerative colitis: coincidence? *Clin Exp Dermatol*. 2021; 47(1):143-144. <https://doi.org/10.1111/ced.14842>
4. Sun Q, Fathy R, McMahon DE, et al. COVID-19 vaccines and the skin: the landscape of cutaneous vaccine reactions worldwide. *Dermatol Clin*. 2021;39(4):653-673. <https://doi.org/10.1016/j.det.2021.05.016>
5. Rodrigues M, Ezzedine K, Hamzavi I, et al. New discoveries in the pathogenesis and classification of vitiligo. *J Am Acad Dermatol*. 2017;77(1):1-13. <https://doi.org/10.1016/j.jaad.2016.10.048>
6. Lane C, Leitch J, Tan X, et al. Vaccination-induced autoimmune vitiligo is a consequence of secondary trauma to the skin. *Cancer Res*. 2004;64(4):1509-1514. <https://doi.org/10.1158/0008-5472.can-03-3227>
7. Arya V, Bansal M, Girard L, et al. Vitiligo at injection site of PEG-IFN- $\alpha$  2a in two patients with chronic hepatitis C: case report and literature review. *Case Rep Dermatol*. 2010;2(2): 156-164. <https://doi.org/10.1159/000320207>
8. van Geel N, Speeckaert R, Mollet I, et al. In vivo vitiligo induction and therapy model: double-blind, randomized clinical trial. *Pigment Cell Melanoma Res*. 2012;25(1):57-65. <https://doi.org/10.1111/j.1755-148X.2011.00922.x>
9. Jacob SE, Blyumin M. Vitiligo-like hypopigmentation with poliosis following treatment of superficial basal cell carcinoma with imiquimod. *Dermatol Surg*. 2008;34(6):844-845. <https://doi.org/10.1111/j.1524-4725.2008.34158.x>
10. Katz EL, Harris JE. Translational research in vitiligo. *Front Immunol*. 2021;12:624517. <https://doi.org/10.3389/fimmu.2021.624517>