



Contents lists available at ScienceDirect

Journal of Hand Surgery Global Online

journal homepage: www.JHSGO.org

Case Report

Pseudogout: A Rare Cause of Acute Carpal Tunnel Syndrome and Acute Guyon Canal Syndrome

Forrest Rackard, MD,^{*} Jorge Lujan-Hernandez, MD,[†] Vijay Vanguri, MD,[‡] Douglas Rothkopf, MD[†]^{*} Department of Orthopedic Surgery, University of Massachusetts Chan Medical School, Worcester, MA[†] Department of Plastic Surgery, University of Massachusetts Chan Medical School, Worcester, MA[‡] Department of Pathology, University of Massachusetts Chan Medical School, Worcester, MA

ARTICLE INFO

Article history:

Received for publication March 28, 2022

Accepted in revised form July 18, 2022

Available online August 19, 2022

Key words:

Pseudogout

Acute carpal tunnel syndrome

Acute Guyon canal syndrome

Gout

Median nerve

Pseudogout is an acute inflammatory arthropathy that often presents as a hot, swollen, painful joint. Rarely, the inflammatory response caused by pseudogout has led to acute neuropathic symptoms of the hand. We present a case of pseudogout causing acute neuropathic symptoms in the median and ulnar nerves, ultimately necessitating urgent surgical decompression. The patient's symptoms were alleviated after surgical decompression. Pseudogout should be considered a rare cause of acute neuropathic compression of the hand. Its management may require surgical intervention and should involve post-operative follow-up with a rheumatologist.

Copyright © 2022, THE AUTHORS. Published by Elsevier Inc. on behalf of The American Society for Surgery of the Hand. This is an open access article under the CC BY-NC-ND license (<http://creativecommons.org/licenses/by-nc-nd/4.0/>).

Crystal arthropathies affecting the hand often present as chronic pathology with intermittent flares of pain and inflammation. Few case studies have shown pseudogout flares associated with neuropathic symptoms, specifically with compression of the median nerve, resulting in acute carpal tunnel syndrome (CTS).^{1–4} Acute deposition of hydroxyapatite crystals has also been implicated in acute CTS, along with tumoral calcium pyrophosphate dihydrate (CPPD) causing compression of the median and ulnar nerves.^{5–7} Here, we present an uncommon case of new onset of pseudogout, presenting in the hand as both acute carpal tunnel syndrome and acute Guyon canal syndrome. The patient provided written informed consent for the use of deidentified health information and images for research and educational purposes.

Case

A 55-year-old right-handed woman with no history of rheumatologic disease presented to the emergency department with 2

days of increased pain, swelling, and progressive numbness in the right hand and all 5 fingers. She denied any trauma, injections, or penetrating injuries to her hand. She had chills and night sweats, but no fever. She denied any similar events in the past. Her medical history was notable for hepatitis C; distant intravenous drug use (heroin, last used 25 years before); and osteoarthritis of the knees, hips, and spine. She denied a personal history of gout, pseudogout, autoimmune disorders, or kidney stones. She reported a family history consistent with rheumatoid arthritis in her paternal grandmother and paternal great aunt.

On physical examination of her hand, there was erythema and swelling most prominent in the hypothenar region, extending proximally into the volar wrist. She was diffusely tender to palpation in the distal volar forearm, wrist, and hand. The volar wrist, along with the thenar and hypothenar compartments, was profoundly taut. She had numbness and paresthesia in the median and ulnar nerve distributions with diminished 2-point discrimination but had normal sensation in the radial nerve distribution. Her motion was severely limited because of pain; however, she could weakly fire all intrinsic and extrinsic hand muscles. She had a palpable radial pulse, and her hand was warm and well-perfused.

The patient was afebrile and hemodynamically stable. The laboratory results revealed white blood cell count of 9,300 cells per cubic millimeter (reference, 4,300–10,800 per cubic

Declaration of interests: No benefits in any form have been received or will be received related directly or indirectly to the subject of this article.

Corresponding author: Forrest Rackard, MD, Department of Orthopedic Surgery, University of Massachusetts Chan Medical School, 55 Lake Avenue N, Worcester, MA 01655.

E-mail address: Forrest.rackard@umassmemorial.org (F. Rackard).

<https://doi.org/10.1016/j.jhsg.2022.07.010>

2589-5141/Copyright © 2022, THE AUTHORS. Published by Elsevier Inc. on behalf of The American Society for Surgery of the Hand. This is an open access article under the CC BY-NC-ND license (<http://creativecommons.org/licenses/by-nc-nd/4.0/>).

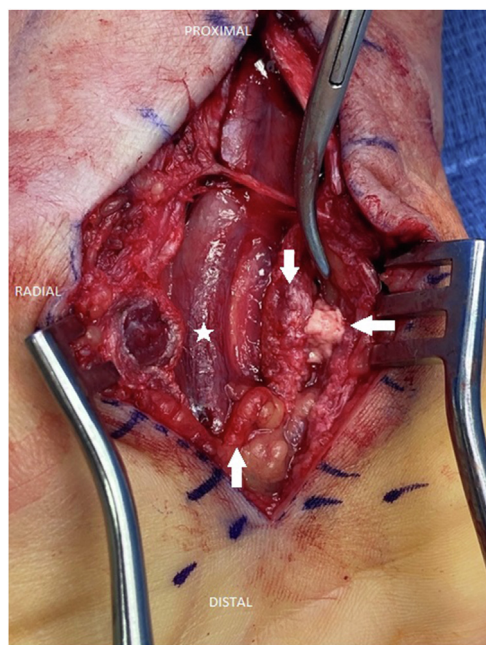


Figure 1. Intraoperative photograph showing crystalline pseudogout within Guyon canal (left arrow). Five-point star indicates median nerve; down arrow indicates transected transverse carpal ligament; left arrow indicates crystalline pseudogout within Guyon canal overlying the ulnar nerve and artery; and up arrow indicates superficial palmar arch.

millimeter), C-reactive protein level of 8.1 mg/L (reference, <10 mg/L), and erythrocyte sedimentation rate of 29 mm/h (reference, 0–30 mm/h). The serum uric acid level was 3.1 mg/dL (reference, 2.4–6 mg/dL). Her basic metabolic panel, complete blood count with differential, and liver function tests were otherwise within normal limits. She was started on intravenous vancomycin and piperacillin/tazobactam with concern for infectious etiology. An x-ray of her right hand showed diffuse soft tissue swelling but was negative for any fracture. Radiographs of her hand were negative for calcium deposits at the triangular fibrocartilage, a site commonly noted for CPPD deposits.⁸ Given the presentation, a computed tomography scan of her right hand was performed to specifically rule out a deep space abscess; however, preliminary reads showed no fluid collection or other infectious processes. Hours later, the radiologist confirmed a small irregular radiopaque calcified mass overlying the hook of the hamate just radial to the ulnar artery and nerve.

Six hours after starting antibiotics, her pain became intractable, with worsening of the paresthesia and numbness. Swelling involved the thenar and hypothenar compartments and the volar wrist. The proximal forearm and other compartments were soft. Because of the clinical concern for developing compartment syndrome, she was subsequently taken to the operating room for exploration, volar wrist incision and drainage, and combined carpal tunnel and Guyon canal releases. Edema was noted, but no frank purulence was encountered during the superficial dissection through the subcutaneous tissue down to the transverse carpal ligament. Upon release of the transverse carpal ligament, there was a considerable hourglass deformity of the median nerve. The motor branch was identified and spared. Exploration of the carpal tunnel revealed more edema but no abscess.

Similarly, the exploration of the space of Parona revealed no abscess. Through the same skin incision, Guyon canal was then released from the level of the superficial palmar arch to the distal

wrist crease. Upon the incision of the volar carpal ligament, a cavity of white, gelatinous material was encountered overlying the hook of the hamate (Fig. 1). Approximately 2 mL of this material was expressible from the cavity. This material went down to the hook of the hamate but was well-contained in this space. It was removed completely; half of the material was sent for pathologic evaluation, including crystallography, and the other half was sent for Gram staining and aerobic, anaerobic, fungal, and mycobacterial cultures. There was an immediate release of pressure on the volar wrist, thenar, and hypothenar compartments, and tension-free primary closure was performed. Rheumatology and infectious disease departments were consulted after surgery because of concern for crystal arthropathy versus possible atypical mycobacterial infection. The patient was discharged on sulfamethoxazole-trimethoprim while the results of the intraoperative cultures were pending. The final tissue pathology results showed dystrophic calcification suggestive of pseudogout (Fig. 2). Aerobic, anaerobic, and mycobacterial cultures were negative. The patient was seen at her 10-day follow-up and was noted to have complete resolution of pain with improvement in her range of motion and paresthesia. She plans to follow-up at the rheumatology department as an outpatient.

Discussion

Pseudogout, which describes the acute deposition of CPPD crystals into articular cartilage, triggers a proinflammatory immune response involving articular phagocytic cells and a resulting cytokine storm, propagating leukocyte and mononuclear cell migration. This results in a warm, painful, swollen joint that can mimic other musculoskeletal pathologies, including septic arthritis, acute calcific tendinitis, gout, rheumatoid arthritis, or primary osteoarthritis.⁹

The first case of acute CTS attributed to pseudogout was reported in 1976 by Spiegel et al.⁸ Since then, there have been 4 other case reports in the published literature. The average age of patients in these reports was 69.8 years; 4 women and 1 man were included. Notably, the range of symptom onset before presentation for most patients was 3–10 days. Interestingly, our patient was relatively young and had a rapid onset of symptoms over 2 days. Most remarkably, she had signs and symptoms of acute ulnar and median nerve compression. Acute compression of the median and ulnar nerves is exceedingly rare, usually attributed to trauma or burns. Yamazaki et al.⁷ presented a case of median and ulnar nerve compression caused by tumoral CPPD disease, with both nerves affected by a 6 × 4-cm cystic mass of the volar wrist that had developed over the course of 1 year. Our patient did not have tumoral CPPD disease; however, she had considerable acute median and ulnar neuropathy. Previous reports of pseudogout causing acute CTS have suggested that CPPD deposits cause direct compression of the median nerve within the carpal tunnel. Chiu et al.¹ reported direct compression of the median nerve by an outpocketing of the anterior capsule of the radiocarpal joint filled with a chalky, whitish substance. Goodwin et al.⁴ found “caseous-like deposits” under the median nerve. Interestingly, no CPPD deposits or gelatinous material were identified in the carpal tunnel of our patient. We hypothesize that the CPPD material found intraoperatively at the radial side of the Guyon canal caused direct compression of the ulnar nerve, with the resultant inflammatory response causing an acute compartment syndrome with concomitant acute median nerve compression.

There is 1 case report of acute calcific tendinitis of the flexor carpi ulnaris tendon causing acute compression of the ulnar nerve.¹⁰ Notably, the patient described in this case report had a

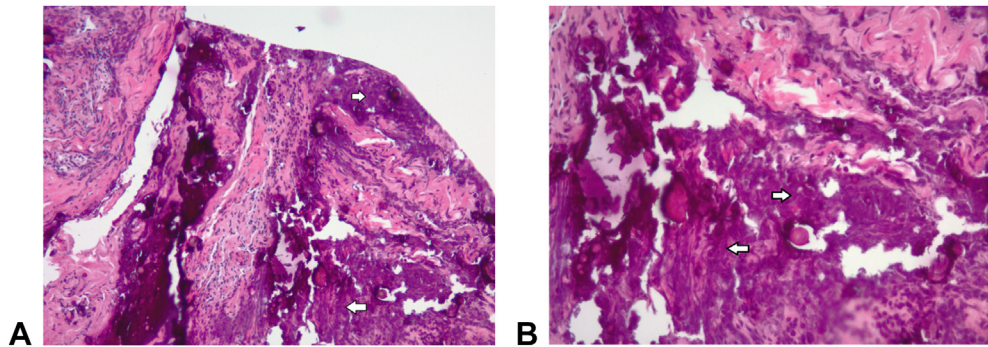


Figure 2. **A** A 5- μ m hematoxylin-eosin–stained section of formalin-fixed, paraffin-embedded tissue with no decalcification. White arrows indicate dense fibrous and fibrovascular tissue with coarse basophilic deposits of calcium phosphate. **B** A 5- μ m hematoxylin-eosin–stained section of formalin-fixed, paraffin-embedded tissue with no decalcification. White arrows indicate calcium phosphate deposits within the fibrous tissue, with no clear pattern of deposition around vessels or other structures (Hematoxylin-eosin stain; magnification: **A** \times 100, **B** \times 200).

presentation similar to ours, with the tenseness of the volar wrist compartment and ulnar paresthesia that progressed to involve the median nerve as well. Intraoperative findings within Guyon canal revealed a mass of soft, chalky material associated with the tendon of the flexor carpi ulnaris was extracted piecemeal. However, the pathologic analysis was more consistent with acute calcific tendinitis of the flexor carpi ulnaris and not crystalline pseudogout. Pathologic analysis of our sample revealed calcium phosphate deposits within the fibrous tissue, with no clear pattern of deposition around vessels or other structures. Interestingly, the deposits were not associated with accompanying inflammation or areas of necrobiosis. According to the pathologist, this was likely because of the lack of adjacent tissue included in the sample and inflammation and fibrosis in the adjacent affected tissue may be present. There was little to no birefringence under polarized light microscopic examination. Although the preservation of polarization can be accomplished by alcohol fixation or nonaqueous methods of fixation, the specimen here was processed routinely with formalin-fixation and staining with hematoxylin-eosin, leading to the absence of appreciable polarization.¹¹ Calcific tendinitis can be difficult to differentiate from pseudogout clinically. Calcific tendinitis is caused by synovial deposition of basic calcium phosphate (hydroxyapatite), which is associated with fibrous and papillary thickening of the synovium. In joint fluids, the aggregated hydroxyapatite crystals often form irregularly shaped microspheroids. Pathological analysis often reveals a pale, laminated psammomatous appearance on decalcified tissue sections. Calcium pyrophosphate dihydrate typically appears dark blue to purple with a distinctly granular appearance on nondecalcified hematoxylin-eosin–stained slides. Decalcified pyrophosphate leaves oval to rounded pools of basophilic material that results in a fibrillar or feathery appearance with sharp and pointed edges, not typically seen in the rounded, psammomatous calcifications in calcific tendinitis.¹² The pathologic findings, in conjunction with the overall histologic and gross findings, were most consistent with acute pseudogout as the primary explanation for the patient's symptomatology.

Surgical decompression and removal of the material promptly alleviated the patient's pain and neuropathy symptoms, similar to the findings of previous reports.^{2–4} With regard to further management of patients with pseudogout, current recommendations include starting a nonsteroidal anti-inflammatory drug (naproxen) at 500 mg twice daily for 5–7 days in patients that present with >24 hours of symptoms. Colchicine dosed at 0.6 mg is recommended for patients who present within the first 24

hours of symptoms onset, with no more than 1.8 mg taken within the first 24 hours. This is followed by 0.6 mg taken twice daily until the attack resolves. Other treatment options for refractory cases include steroid injections and oral glucocorticoids; however, care must be taken to rule out the presence of infection before initiating these treatments.¹³ Our patient was started on intravenous antibiotics before intraoperative culture collection due to concern for a possible infection; she was discharged on 10 days of oral sulfamethoxazole-trimethoprim. Although the culture results were negative, a previous study has shown that patients who receive preoperative antibiotics before the debridement of upper extremity infections are significantly more likely to have negative cultures at the time of debridement, with even 1 dose of antibiotics reaching significance ($P < .01$).¹⁴ Clinicians should be wary of possible concomitant infection with pseudogout given the similar presentations, along with the increase in negative cultures that can occur with the preoperative initiation of antibiotics.

The acute inflammatory response caused by pseudogout can present as a challenging diagnostic scenario and has been implicated in acute nerve compression necessitating surgical intervention. This is a unique case of nontumoral pseudogout causing acute compartment syndrome with neuropathic symptoms of the median and ulnar nerves. Pseudogout should be included in the differential diagnosis of a patient presenting with atraumatic, acutely neuropathic symptoms associated with swelling and pain that do not appear to have an infectious etiology.

References

1. Chiu KY, Ng WF, Wong WB, Choi CH, Chow SP. Acute carpal tunnel syndrome caused by pseudogout. *J Hand Surg Am.* 1992;17(2):299–302.
2. Lewis SL, Fiddian NJ. Acute carpal tunnel syndrome a rare complication of chondrocalcinosis. *Hand.* 1982;14(2):164–167.
3. Rate AJ, Parkinson RW, Meadows TH, Freemont AJ. Acute carpal tunnel syndrome due to pseudogout. *J Hand Surg Br.* 1992;17(2):217–218.
4. Goodwin DR, Arbel R. Pseudogout of the wrist presenting as acute median nerve compression. *J Hand Surg Br.* 1985;10(2):261–262.
5. Suresh SS, Raniga S, Shanmugam V, George M, Zaki H. Carpal tunnel syndrome due to hydroxyapatite crystal deposition disease. *J Hand Microsurg.* 2013;5(2):96–99.
6. Verfaillie S, De Smet L, Leemans A, Van Damme B, Fabry G. Acute carpal tunnel syndrome caused by hydroxyapatite crystals: a case report. *J Hand Surg Am.* 1996;21(3):360–362.
7. Yamazaki H, Uchiyama S, Kato H. Median nerve and ulnar nerve palsy caused by calcium pyrophosphate dihydrate crystal deposition disease: case report. *J Hand Surg Am.* 2008;33(8):1325–1328.

8. Spiegel PG, Ginsberg M, Skosey JL, Kwong P. Acute carpal tunnel syndrome secondary to pseudogout: case report. *Clin Orthop Relat Res.* 1976;120:185–187.
9. Kohn NN, Hughes RE, McCarty DJ Jr, Faires JS. The significance of calcium phosphate crystals in the synovial fluid of arthritic patients: the "pseudogout syndrome". II. Identification of crystals. *Ann Intern Med.* 1962;56:738–745.
10. Yasen S. Acute calcific tendinitis of the flexor carpi ulnaris causing acute compressive neuropathy of the ulnar nerve: a case report. *J Orthop Surg (Hong Kong).* 2012;20(3):414–416.
11. Shidham V, Chivukula M, Basir Z, Shidham G. Evaluation of crystals in formalin-fixed, paraffin-embedded tissue sections for the differential diagnosis of pseudogout, gout, and tumoral calcinosis. *Mod Pathol.* 2001;14(8):806–810.
12. O'Connell JX. Pathology of the synovium. *Am J Clin Pathol.* 2000;114(5):773–784.
13. Zhang W, Doherty M, Pascual E, et al. EULAR recommendations for calcium pyrophosphate deposition. Part II: management. *Ann Rheum Dis.* 2011;70(4):571–575.
14. Dutton LK, Hinchcliff KM, Logli AL, Mallett KE, Suh GA, Rizzo M. Preoperative antibiotics influence culture yield in the treatment of hand, wrist, and forearm infections. *JB JS Open Access.* 2022;7(1):e21.00084.