

eScholarship@UMassChan

Two Cases of Lyme Arthritis in Winter In New England: A Case Series

Item Type	Poster
Authors	Baima, Jennifer;Woo, Lauren
DOI	10.13028/0517-r310
Rights	Copyright the Author(s)
Download date	2024-12-13 14:29:08
Link to Item	http://hdl.handle.net/20.500.14038/42978

CASE DESCRIPTION

Case: Patient 1: 26-year-old male who presented in March with severe right knee pain and swelling for two weeks. Patient 2: 24-year-old male who presented in December with progressive right knee and calf pain for one week. Neither patient reported fever, chills, or rashes.

Background: Patient 1 had a previous episode 1 month prior which resolved spontaneously. The second episode progressed with pain from knee to foot, and numbness on top of the foot. He had no known history of tick bites, travel, or trauma, but endorsed contact with a dog.

Patient 2 had been fishing in the woods a few weeks prior with no trauma and no known history of tick bites. Ultrasound at ED showed no DVT.

Exam: Patient 1: Right knee effusion with no erythema. Limited range of motion in right knee in all planes and pain on flexion. Diffuse joint line tenderness, McMurray's test positive, pain with ligamentous testing but no frank laxity.

Patient 2: Right knee effusion with no erythema. Right knee lacking 5 degrees of extension, pain on flexion to 95 degrees. McMurray's test producing mild pain. Mild joint line tenderness, moderate popliteal and calf tenderness. No tenderness over MCL or LCL; no frank laxity but mild pain with ligamentous testing.

Diagnostics: Patient 1: synovial fluid of the joint showed WBC count 44,467 and was positive for Lyme PCR.

Patient 2: synovial fluid of the joint showed WBC count 37,520 and had positive Lyme PCR.

MR Imaging: Patient 1: ACL laxity and inflammation. Patient 2: bone contusion, ACL laxity, and inflammation.

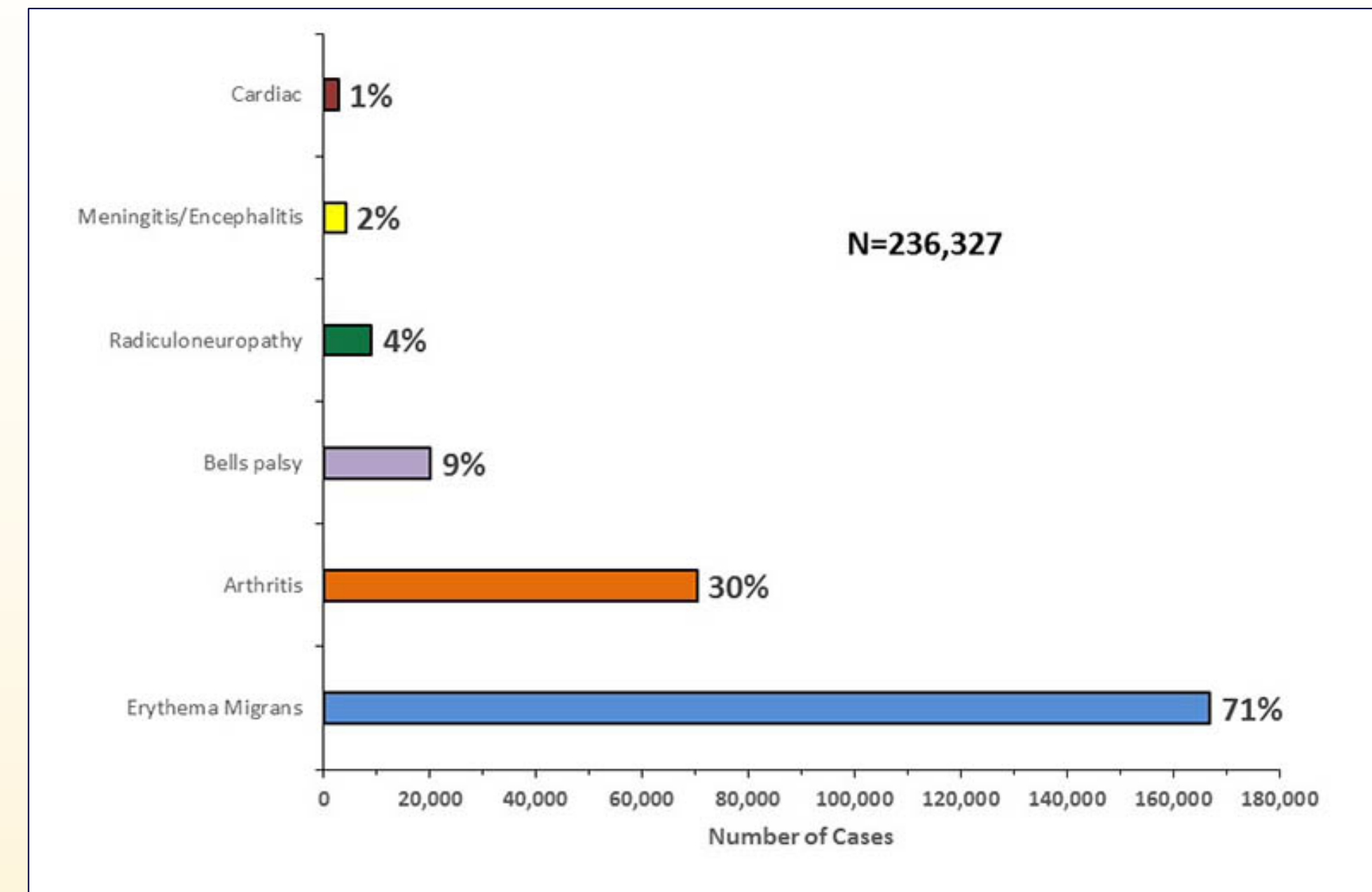


Figure 1: Clinical Manifestations of Confirmed Lyme Disease - United States 2001-2015. <https://www.cdc.gov/lyme/stats/graphs.html>

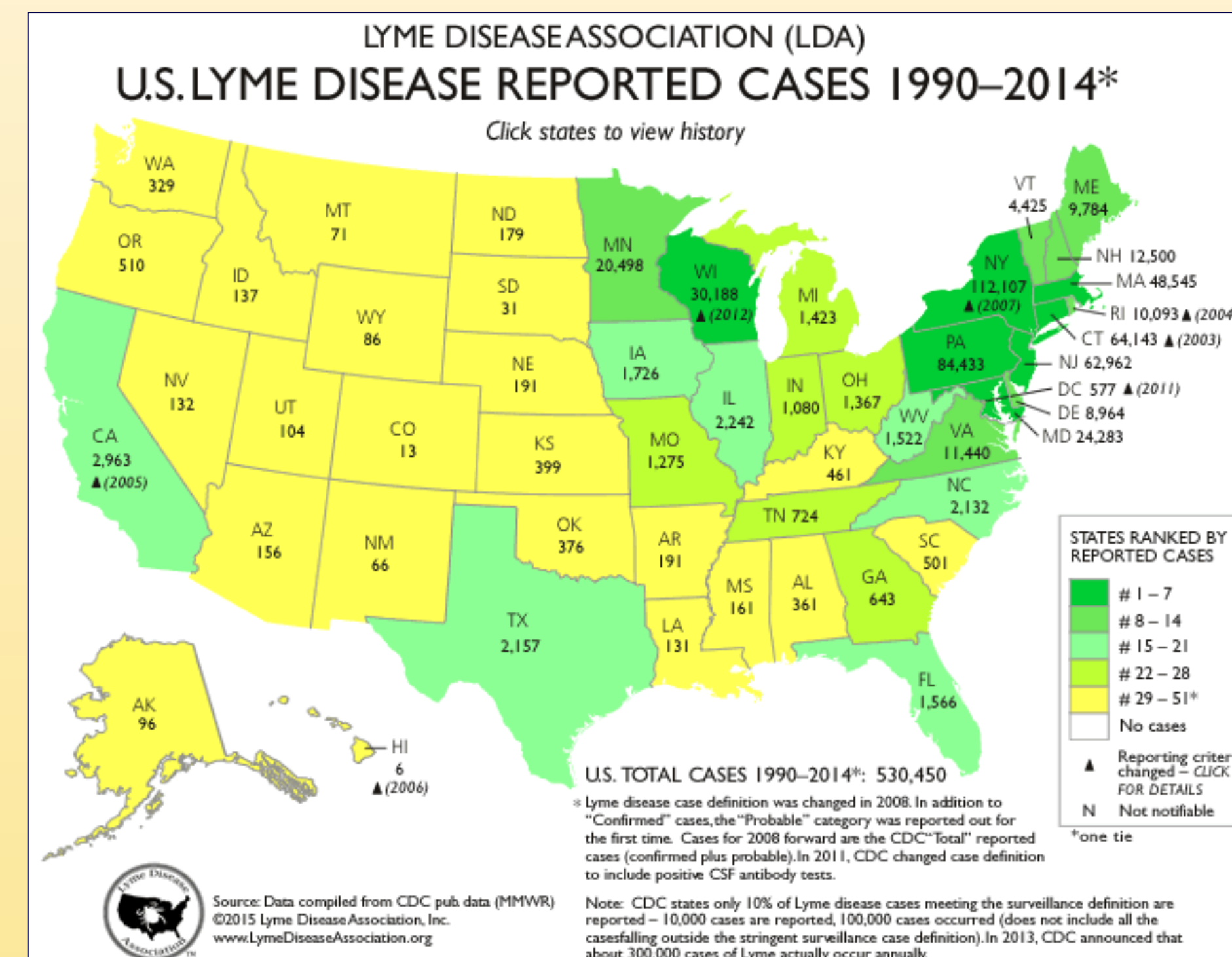


Figure 2: US Lyme Disease Reported Cases 1994-2014. https://www.lymediseaseassociation.org/LDA_Apps/content/Maps/index.html

References

- Arvikar, SL. and Steere, AC. Diagnosis and Treatment of Lyme Arthritis. *Infect Dis Clin North Am.* 2015 Jun;29(2):269-80.
- Hu, Linden T. In the Clinic: Lyme Disease. *Annals of Internal Medicine.* 2016 May 3;164(9):ITC65-ITC80.

DISCUSSION

Lyme disease is transmitted by nymphal *Ixodes scapularis* ticks, which appear in late spring and early summer; however, Lyme arthritis may occur during any season. Ticks infected with the spirochete *B. burgdorferi* are primarily found in the Northeastern and upper Midwestern US.

For Lyme transmission to occur, the spirochete must move from the tick midgut to the salivary glands and into the new host, which takes 24-48 hours. Early localized disease occurs 3-30 days after tick exposure and presents as erythema migrans; early disseminated disease can occur days to months after exposure and includes monoarticular or oligoarticular arthritis, with or without systemic symptoms. *B. burgdorferi* dissemination to joints, tendons, or bursae early in infection can be an asymptomatic event or present with transient arthralgias. Lyme arthritis presents later, with an adaptive immune response that results in spirochetal killing. Intermittent or chronic arthritis occurs in late disseminated disease, months to years after initial exposure.

Management: Treatment included doxycycline for both patients. Patient 2 underwent repeat aspiration for recurrent effusion with symptomatic relief and was prescribed physical therapy for quadriceps and hip abductor stabilization.

Outcome: In both cases, knee pain and effusion resolved with doxycycline treatment.

CONCLUSIONS

- ◆ Lyme arthritis can present at any time of year, and clinical suspicion should remain high in endemic regions, even without a known history of tick exposure or erythema migrans rash.