




eScholarship@UMassChan

Spontaneous abscess with intraventricular rupture in an immunocompetent adult without prior neurosurgical intervention

Item Type	Case Report
Authors	Smith, Jordan L;Cruz-Gordillo, Peter;Luiselli, Gabrielle;Daci, Rrita;Owusu-Adjei, Brittany;Ogagan, Charles;Moses, Ziev B
Citation	Smith JL, Cruz-Gordillo P, Luiselli G, Daci R, Owusu-Adjei B, Ogagan C, Moses ZB. Spontaneous Propionibacterium Acnes abscess with intraventricular rupture in an immunocompetent adult without prior neurosurgical intervention. Clin Case Rep. 2022 Jan 25;10(1):e05216. doi: 10.1002/ccr3.5216. PMID: 35106159; PMCID: PMC8787723.
DOI	10.1002/ccr3.5216
Journal	Clinical case reports
Rights	This is an open access article under the terms of the Creative Commons Attribution-NonCommercial License, which permits use, distribution and reproduction in any medium, provided the original work is properly cited and is not used for commercial purposes. © 2022 The Authors.;Attribution-NonCommercial 4.0 International
Download date	2026-03-14 22:46:41
Item License	http://creativecommons.org/licenses/by-nc/4.0/
Link to Item	https://hdl.handle.net/20.500.14038/52054

CASE REPORT

Spontaneous *Propionibacterium Acnes* abscess with intraventricular rupture in an immunocompetent adult without prior neurosurgical intervention

Jordan L. Smith^{1,2}  | Peter Cruz-Gordillo^{1,2} | Gabrielle Luiselli^{2,3}  | Rrita Daci^{2,4} | Brittany Owusu-Adjei^{2,4} | Charles Ogagan^{2,3}  | Ziev B. Moses^{2,5}

¹Medical Scientist Training Program, University of Massachusetts Chan Medical School, Worcester, Massachusetts, USA

²Department of Neurological Surgery, University of Massachusetts Chan Medical School, Worcester, Massachusetts, USA

³School of Medicine, University of Massachusetts Chan Medical School, Worcester, Massachusetts, USA

⁴University of Massachusetts Chan Medical School Neurological Surgery Residency, Worcester, Massachusetts, USA

⁵UMass Memorial Health Care, Worcester, Massachusetts, USA

Correspondence

Ziev Moses, Department of Neurological Surgery, University of Massachusetts Chan Medical School, Worcester, MA 01605, USA.
Email: ziev.moses@umassmemorial.org

Funding information

J.L.S. was supported by the National Cancer Institute F30CA239483.P.C.G was supported by the University of Massachusetts Medical School Cancer Biology T32CA130807

Abstract

Previously viewed as a culture contaminant, *Propionibacterium Acnes* can cause infection following neurosurgical intervention. Its role in brain abscess in the immunocompetent, surgically naïve population has been infrequently reported. Herein, we describe an immunocompetent 55-year-old man with no risk factors found to have a thalamic abscess with intraventricular rupture.

KEYWORDS

brain abscess, immunocompetent, interventricular rupture, polymicrobial infection, propionibacterium acnes

1 | INTRODUCTION

A brain abscess is a site of focal infection and inflammation that has crossed the blood-brain barrier. Over the past five decades, the rate of patients that make a full recovery from a brain abscess has risen from 33% to 70%.^{1,2} Despite these successes, significant morbidity and mortality remains associated with brain abscesses requiring clinical optimization.

Patients with a brain abscess classically present with a triad of headache, fever, and focal neurological deficits.

Importantly, this symptom triad occurs only in 20% of patients. The majority of patients who develop a brain abscess have a predisposing condition (86%), such as otitis, mastoiditis, sinusitis, and meningitis.² Brain abscesses rarely develop in patients without any predisposing factors, or previous neurosurgical intervention.²

In immunocompetent patients, approximately 95% of brain abscess cases are of bacterial origin, usually polymicrobial. The most commonly identified microorganisms are streptococci (i.e., *S. mitius*, *S. mutans*, *S. salivarius*), staphylococci (i.e., *S. aureus*), anaerobes (i.e., *actinomyces*,

Jordan L. Smith and Peter Cruz-Gordillo are contributed equally.

This is an open access article under the terms of the Creative Commons Attribution-NonCommercial License, which permits use, distribution and reproduction in any medium, provided the original work is properly cited and is not used for commercial purposes.

© 2022 The Authors. *Clinical Case Reports* published by John Wiley & Sons Ltd.

bacteroides), and Enterobacteriaceae.³ As a result, standard-of-care empirical medical treatment calls for the use of a third-generation cephalosporin and metronidazole. Neurosurgical intervention, in the form of abscess aspiration and placement of an external ventricular drain (EVD), can serve a dual purpose: collection of sample fluid for diagnostic analysis, and relief of intracranial pressure caused by the abscess. Despite these actions, upward of 1/3 of patients have culture-negative specimens.

1.1 | Use of 16S sequencing in brain abscess characterization

For patients with culture-negative specimens, 16S rRNA sequencing has presented an alternative diagnostic strategy to identify causal microbes.^{4–9} 16S rRNA sequencing works by amplifying bacterial genes directly from clinical samples; however, like most laboratory methods, 16S sequencing is not foolproof.⁵ 16S sequencing is prone to environmental contaminants introduced during sample collection and processing. Finally, to identify species of fungal origin, additional sequencing methods need to be used like 29S rRNA sequencing or internal transcribed sequencing (ITS).^{10–12} Similar to standard culture methods, use of sequencing for detection of causal microbes requires clinical correlation.

1.2 | *Propionibacterium Acnes* brain abscesses

Previously thought of as primarily a culture contaminant, *P. acnes* has been more recently recognized as an infrequent, and often indolent, cause of infection after neurosurgical intervention. *P. Acnes* is a gram-positive bacterium that is a known colonizer of the skin. Typically, these infections have a wide degree of variance in presentation (i.e., extradural, subdural infections, brain abscesses, and meningitis) and in temporality (i.e., weeks to years after neurosurgical procedures).^{13–17} There are only three reports of *P. Acnes* causing a brain abscess in a patient without known risk factors (i.e., immunosuppression), and without prior instrumentation or neurosurgical intervention (Table 1).^{18,19,24} Herein, we describe a case of an immunocompetent man without prior neurosurgery, and predisposing factors who presented with a *P. Acnes* brain abscess with intraventricular rupture.

2 | ILLUSTRATIVE CASE

A 55-year-old man with a past medical history significant of hypertension presented to an outside hospital with four

days of worsening throbbing headache, vomiting, and feeling nauseated. At the outside hospital, imaging was obtained. Head CT showed a hypodensity in his left thalamus with surrounding edema. He was subsequently transferred for emergent neurosurgical evaluation.

At presentation, the patient was febrile to 101.7°F, endorsing several days of throbbing bifrontal headache, nausea, and vomiting. He did not have a history of recent illness, travel, immune compromise, malignancy, environmental exposures, intravenous drug use, previous instrumentation, neurosurgical intervention, or dental procedures. He was in a sexually monogamous relationship. His review of systems was unremarkable. On examination, the patient had no focal neurological deficits and was alert and oriented. While in the ER, he was hyponatremic (128 mEq/L), and had a mildly elevated white count ($11.9 \times 10^3/\mu\text{l}$). He was started on 3% hypertonic saline for his gross hyponatremia.

MRI imaging confirmed a left caudate head abscess ($1.7 \times 1.0 \times 1.1$ cm) with left lateral ventriculitis, moderate vasogenic edema around the ruptured abscess, and left lateral ventriculomegaly (Figure 1). The patient underwent an extensive toxicology and infectious disease workup including peripheral blood cultures. His toxicology results were unrevealing, and he was later found to be negative for HIV, syphilis, tuberculosis, gonorrhea, chlamydia, and toxoplasmosis. The patient was admitted to the neurological intensive care unit, and empirically started on ceftriaxone, metronidazole, and vancomycin.

2.1 | Differential diagnosis, investigations, treatment

The patient spent a total of 24-days in critical care, and thirty total days hospitalized. On hospital day (HD) 1, the patient was newly confused, somnolent, and with a pronator drift on the right side. The patient was emergently brought to the operating room for placement of an extra-ventricular drain, and to obtain a specimen of CSF for infectious etiology workup. A left frontal EVD was placed, aspirate obtained, and the patient improved post-operatively, with no focal neurologic deficits.

A lumbar puncture (LP) was subsequently performed on hospital day (HD) 2. Analysis of the cerebrospinal fluid (CSF) from HD2 was suggestive of a bacterial infection: hypoglycemia (11 mg/dl), hyperproteinemia (881 mg/dl), and an elevated white blood cell count ($12,222$ cells/mm³) with a neutrophil predominance (94%); no organisms were seen.

Five days after EVD placement, an additional LP was performed, and CSF was sent for 16S rRNA and fungal 28S, ITS sequencing. An interval MRI was concerning for intraventricular spread, and he was continued on

TABLE 1 Summary of reported intracranial *Propionibacterium Acnes* abscess

Reference	Age	Sex	Prior neurosurgical intervention	Primary abscess location	Method of diagnosis	Isolated microbes	Antimicrobial therapy
Ramos et al., 1995 ^{18*}	18	F	None	Intraparenchymal	Surgical Biopsy and Culture	<i>P. Acnes</i> , <i>S. anginosus</i>	Penicillin Chloramphenicol
	64	M	None	Intraparenchymal	Surgical Biopsy and Culture	<i>P. Acnes</i> , Peptostreptococcus	Penicillin Ampicillin
	18–69* (9 total patients)	M/F	All had prior intervention	Subdural, epidural and parenchymal	Surgical Biopsy and Culture	<i>P. Acnes</i>	Penicillin Cephalosporins, most common
Bazari et al., 2003 ¹⁶	61	F	18 months s/p parasagittal craniotomy	Surgical Site	Surgical Biopsy and Culture	<i>P. Acnes</i>	Cefotaxime Clindamycin
Nisbet et al., 2007 ¹³	23–77* (28 total patients)	M/F	All had prior intervention	Mixed locations	Surgical Biopsy, Culture	<i>P. Acnes</i>	Penicillin Cephalosporins, most common
Kranick et al., 2009 ¹⁵	70	M	10 years s/p subdural hematoma evacuation	L posterior parietal lobe	Surgical biopsy and culture	<i>P. Acnes</i>	Vancomycin
Chung et al., 2011 ¹⁷	70	M	13 months s/p decompressive craniectomy and partial lobectomy	Postoperative wound	Surgical biopsy culture; 16S rRNA gene sequencing	<i>P. Acnes</i>	Vancomycin, Ceftriaxone
Zaffiri et al., 2013 ²⁴	79	M	None	Anterior R frontal lobe	Maxillary sinus culture	<i>P. Acnes</i>	Vancomycin, meropenem
Odonukan et al., 2016 ¹⁹	49	M	None	L thalamus	Surgical biopsy and culture	<i>P. Acnes</i>	Meropenem, Vancomycin, Cefepime, Metronidazole
Frid et al., 2017 ¹⁴	61	M	9 months s/p brain stimulation (DBS)	L thalamus	Surgical removal of hardware and culture	<i>P. Acnes</i>	Ceftriaxone
	53	F	20 weeks s/p DBS	R thalamus	Surgical removal of hardware and culture	<i>P. Acnes</i>	Daptomycin
	65	M	13 weeks s/p DBS	R thalamus	Surgical removal of hardware and culture	<i>P. Acnes</i>	Ceftriaxone

Note: Reported cases include both spontaneous intracranial *P. Acnes* abscess and *P. Acnes* abscess following neurosurgical intervention.

*Report contains multiple patients.

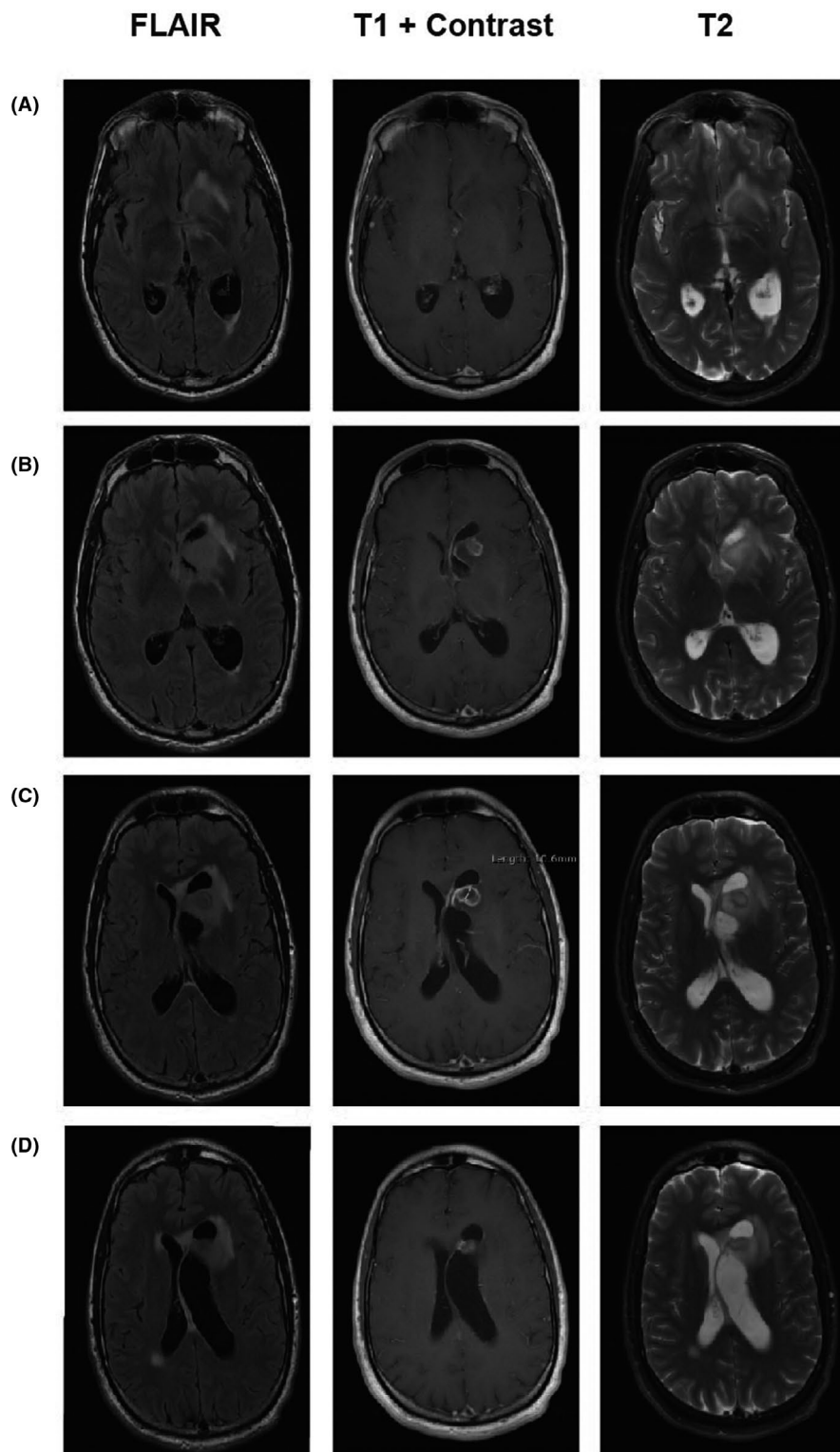


FIGURE 1 Magnetic resonance imaging at patient presentation shows left caudate abscess with left ventriculitis. (A–D) Representative axial sections. FLAIR, T1 and T2 sequence, respectively. T1 Rim enhancing lesion 10.6 mm

ceftriaxone, metronidazole, and vancomycin while cultures were pending. On HD9, the cerebral aspirate from EVD placement grew *Propionibacterium Acnes*. His antibiotics were de-escalated to IV penicillin for specific coverage of *P. Acnes*.

On HD11, the patient experienced acute aphasia and was found to be seizing. His EVD was not draining. His

EVD was flushed, and he was started on levetiracetam. His aphasia resolved, and he did not have any subsequent seizures following levetiracetam administration. Out of an abundance of caution, he was restarted on broad-spectrum antibiotics.

The following day, HD13, the ITS and 16S rRNA ribosomal sequencing returned with *Cladosporium*, and

non-*aeruginosa pseudomonas*, respectively. Infectious disease felt that both specimens isolated were *unlikely* the cause of his infection, and inconsistent with his clinical picture. However, given the morbidity and mortality associated with *Cladosporium* infection,²⁰ coverage was conservatively expanded to include the anti-fungals voriconazole and amphotericin B in the regimen. Specific coverage for non-*aeruginosa pseudomonas* was not started. The patient developed acute kidney injury on HD15. Amphotericin B was stopped. Repeat CSF cultures were obtained from the EVD and were sent for sequencing. Yet, neither of these samples returned evidence of any organisms, suggesting that initial 16S and ITS results were contaminants.

2.2 | Outcome and follow-up

From HD14 to HD24, the patient continued to improve with reduction in headaches, no focal findings on examination, and minimal drainage from his EVD. Once on the floor, the patient was continued on IV ceftriaxone, metronidazole, vancomycin, and oral voriconazole. The surveillance head CT was stable. With the recommendation of the infectious disease service, he was discharged on HD30 with IV ceftriaxone, metronidazole, vancomycin, and oral voriconazole for six-eight weeks of IV treatment, and 1–2 years of oral voriconazole treatment, respectively.

At his 2-month follow-up, infectious disease discontinued the IV antibiotics, but recommended continuing with oral voriconazole for 1–2 additional years given the severe morbidity and mortality associated with an *unlikely* *Cladosporium* infection.^{11,20} Imaging at 2 months post-discharge showed both resolution of enhancement and DWI restriction, no hydrocephalus suggestive of resolution of the abscess (Figure 2). To date, the patient is recovering well with no seizures or focal deficits.

3 | DISCUSSION

Herein, we describe the case of a 55-year-old previously well man with a past medical history significant only of hypertension, and no predisposing risk factors, presenting with fever, vomiting, and throbbing headache found to have a left thalamic abscess with interventricular rupture. Cerebral aspirate obtained from placement of the frontal EVD of the abscess grew *P. Acnes* on hospital day 9. Indeed, return of positive bacterial culture was consistent with the findings of the lumbar puncture performed on day 2, marked by low glucose, and leukocytosis with a neutrophil predominance that indicated an infection of bacterial origin. Furthermore, the return of *P. Acnes* on day 9, seemingly late, is *consistent* with the indolent

nature of *P. Acnes*, which has been previously reported by multiple groups.¹⁷ Importantly, the slow growth of the *P. Acnes* culture is neither necessarily indicative of contamination nor signaling poor reliability of the culture results to clinicians.

In this circumstance, bacterial and fungal rRNA sequencing did not further clarify the clinical picture. Specifically, initial results returned *Cladosporium* species, while repeat sequencing four days later was negative, suggesting that the finding was likely a contaminant. The discrepancy in sequencing results presented a significant conundrum. The significant morbidity and mortality (reaching 70%^{11,20}) associated with cerebral infection of *Cladosporium* prompted treatment of systemic anti-fungals (i.e., amphotericin B, voriconazole). However, it is important to note that this intervention is not benign. It is associated with a host of systemic toxicities, perhaps most prominently, significant nephrotoxic and hepatotoxic effects.

In this case, it was determined that, despite the low likelihood of a true fungal infection, the patient should be treated as if the first fungal sequencing result was positive due to the potentially high mortality of an untreated *Cladosporium* infection. While the patient's initial LP was presented classically for a bacterial infection, the sensitivity and specificity of fungal sequencing in brain abscess needs further investigation. One report suggests that in 90 mixed clinical samples, the concordance between IFS sequencing and fungal culture was 94%.²¹ Indeed, amphotericin need to be stopped for this patient due to nephrotoxicity, and the patient continued on voriconazole.

Specifically, reports of 16S RNA sequencing sensitivity and specificity across clinical specimens seem to vary greatly, likely due to sample collection, preparation, and bioinformatics technical challenges. For example, across multiple clinical specimens including joint aspirates, brain abscess, and prosthetic valves, Akram et al found a sensitivity of 58% (CI 28.59%–83.5%) and specificity of 85% (61.13%–96%) for 16S RNA sequencing.²² Indeed, other groups have reported low specificity and sensitivity of 16S RNA sequencing. Given the variability in 16S sensitivity, the absence of *P. Acnes* in the patient's initial sequence results was unsurprising. Further, prior to the collection of CSF samples for sequencing, the patient was treated with *P. Acnes* sensitive antibiotics. Finally, most standard protocols regularly filter out *P. Acnes* as a contaminant if it represents less than 10% of the isolated population.²³

This case, and the few other reports of *P. Acnes* infection in an immunocompetent adult bring several important points for consideration including: what is the route of translocation for *P. Acnes* in an immunocompetent patient, should standard empirical treatment of brain abscesses include *P. Acnes* coverage, and when should 16S rRNA

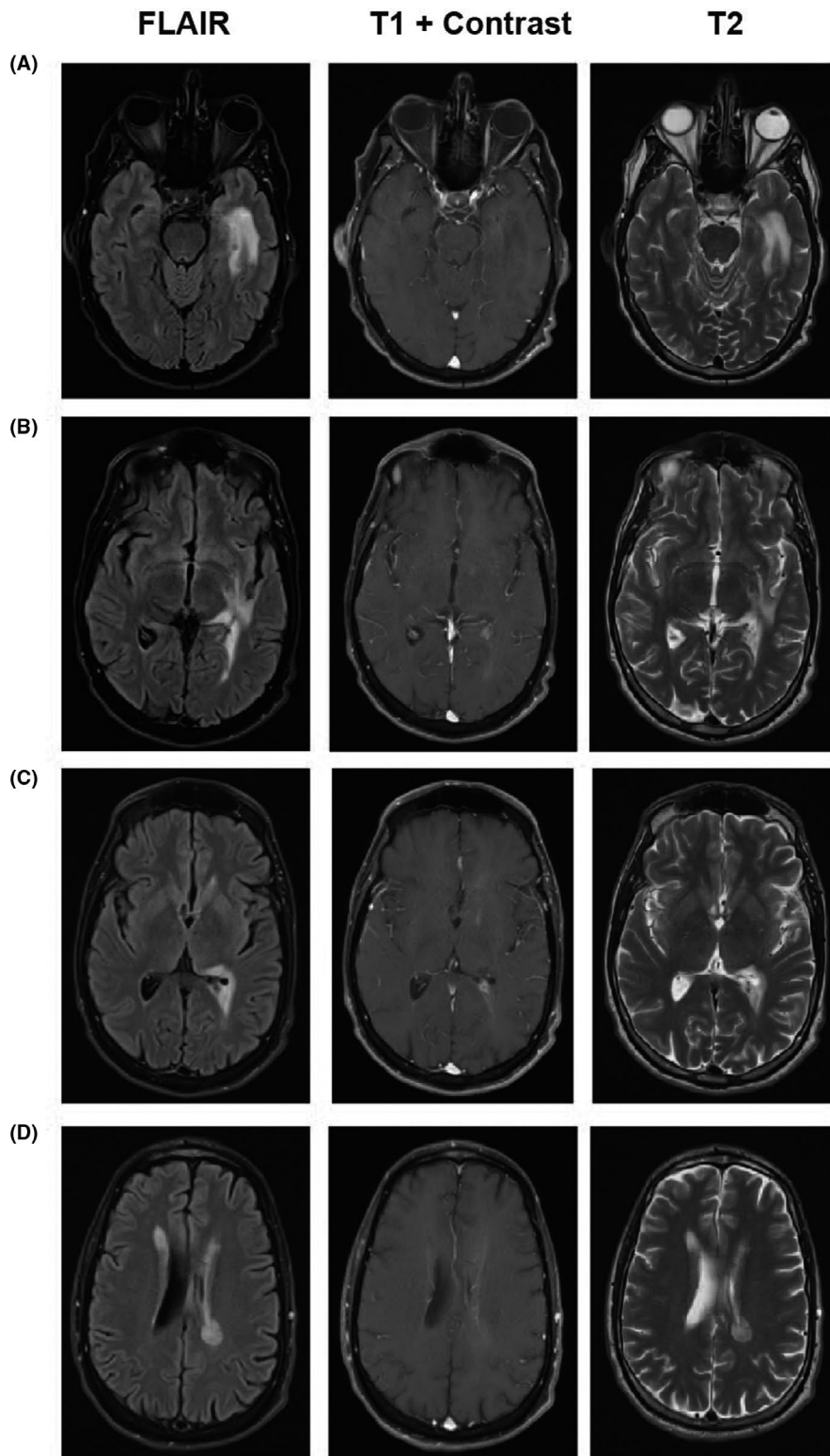


FIGURE 2 Follow-up magnetic resonance imaging show resolution of left caudate abscess with residual edema. (A–E) Representative axial serial sections, FLAIR, T1, T2, respectively

sequencing be employed in a patient with an unknown infection source? As discussed previously, *P. Acnes* is a part of the normal flora of the skin, and more importantly the scalp. *P. Acnes* may translocate across small breaks in the skin, fragile or porous bone, and infect a proportion of people who are either genetically susceptible or have subclinical immunodeficiencies. Luckily, most reports

of *P. Acnes* CNS infections demonstrate that *P. Acnes* is nearly always sensitive to penicillin. Furthermore, cephalosporins, vancomycin, and clindamycin provide adequate coverage.¹⁵

In summary, herein we report a case of an immunocompetent man found to have a *P. Acnes* left thalamic abscess with interventricular rupture. This case adds to the

current paucity of literature demonstrating that *P. Acnes* can cause CNS infection in an immunocompetent patient and should be considered in the differential for the cause of cerebral abscess. Further, clinicians should be aware of the relative delay in culturing *P. Acnes*. It can take upward of ten days for positive cultures to return. Finally, while 16S rRNA sequencing is not routinely performed on every brain abscess, we do recommend that it maintains utility in cases where initial cultures remain negative for greater than 10 days, or if the patient is worsening despite adequate coverage of standard microorganisms.

ACKNOWLEDGMENT

We thank the University of Massachusetts Medical School Department of Neurological Surgery for their support of this case report.

CONFLICT OF INTEREST

None.

AUTHOR CONTRIBUTIONS

JS, PC, and ZM conceived and designed the manuscript. JS, PC, and GL wrote the manuscript, and analyzed cases. JS, PC, GL, RD, BOA, and CO critically revised the manuscript. ZM supervised the study.

SUBMISSION STATEMENT

This manuscript is original and has not been submitted elsewhere in part or in whole.

CONSENT

Written informed consent was obtained from the patient to publish this report in accordance with the journal's patient consent policy.

DATA AVAILABILITY STATEMENT

There is no associated data with this manuscript that requires deposition or availability.

ORCID

Jordan L. Smith  <https://orcid.org/0000-0003-0460-0647>

Gabrielle Luiselli  <https://orcid.org/0000-0001-9051-8425>

Charles Ogagan  <https://orcid.org/0000-0001-7596-0071>

REFERENCES

- Brouwer MC, Tunkel AR, McKhann GM, van de Beek D. Brain abscess. *N Engl J Med*. 2014;371(5):447-456.
- Brouwer MC, Coutinho JM, van de Beek D. Clinical characteristics and outcome of brain abscess: systematic review and meta-analysis. *Neurology*. 2014;82(9):806-813.
- Cantiera M, Tattevin P, Sonnevile R. Brain abscess in immunocompetent adult patients. *Rev Neurol (Paris)*. 2019;175(7-8):469-474.
- Raoult M, Masalma MA, Armougom F, et al. The expansion of the microbiological spectrum of brain abscesses with use of multiple 16S ribosomal DNA sequencing. *Clin Infect Dis*. 2009;48(9):1169-1178.
- Kommedal Ø, Wilhelmssen MT, Skrede S, et al. Massive parallel sequencing provides new perspectives on bacterial brain abscesses. *J Clin Microbiol*. 2014;52(6):1990-1997.
- Mishra AK, Dufour H, Roche PH, Lonjon M, Raoult D, Fournier PE. Molecular revolution in the diagnosis of microbial brain abscesses. *Eur J Clin Microbiol Infect Dis*. 2014;33(12):2083-2093.
- Tsai JC, Teng LJ, Hsueh PR. Direct detection of bacterial pathogens in brain abscesses by polymerase chain reaction amplification and sequencing of partial 16S ribosomal deoxyribonucleic acid fragments. *Neurosurgery*. 2004;55(5):1154-1162.
- Al Masalma M, Lonjon M, Richet H, et al. Metagenomic analysis of brain abscesses identifies specific bacterial associations. *Clin Infect Dis*. 2012;54(2):202-210.
- Al Masalma M, Armougom F, Scheld WM, et al. The expansion of the microbiological spectrum of brain abscesses with use of multiple 16S ribosomal DNA sequencing. *Clin Infect Dis*. 2009;48(9):1169-1178.
- Lin J-H, Wu Z-Y, Gong L, et al. Complex microbiome in brain abscess revealed by whole-genome culture-independent and culture-based sequencing. *J Clin Med*. 2019;8(3):351.
- Garzoni C, Markham L, Bijlenga P, Garbino J. Cladophialophora bantiana: a rare cause of fungal brain abscess. Clinical aspects and new therapeutic options. *Med Mycol*. 2008;46(5):481-486.
- Cheng C, Sun J, Zheng F, Wu K, Rui Y. Molecular identification of clinical "difficult-to-identify" microbes from sequencing 16S ribosomal DNA and internal transcribed spacer 2. *Ann Clin Microbiol Antimicrob*. 2014;13:1.
- Nisbet M, Briggs S, Ellis-Pegler R, Thomas M, Holland D. Propionibacterium acnes: an under-appreciated cause of post-neurosurgical infection. *J Antimicrob Chemother*. 2007;60(5):1097-1103.
- Frid I, P Lewis R, Marsans M, Farrokhi FR. Propionibacterium acnes infection with intracerebral abscess in deep brain stimulation. *J Spine Neurosurg*. 2017;06(05):1-3.
- Kranick SM, Vinnard C, Kolson DL. Propionibacterium acnes brain abscess appearing 10 years after neurosurgery. *Arch Neurol*. 2009;66(6):793-795.
- Barazi SA, Gnanalingham KK, Chopra I, Dellen JV. Delayed post-operative intracerebral abscess caused by Propionibacterium acnes: case report and review of the literature. *Br J Neurosurg*. 2003;17(4):336-339.
- Chung S, Kim JS, Seo SW, et al. A case of brain abscess caused by Propionibacterium acnes 13 months after neurosurgery and confirmed by 16S rRNA gene sequencing. *Korean J Lab Med*. 2011;31(2):122-126.
- Ramos J-M, Esteban J, Soriano F. Isolation of propionibacterium acnes from central nervous system infections. *Anaerobe*. 1995;1(1):17-20.
- Odukanan OW, Masannat F, Baka JJ. Propionibacterium acnes brain abscess in an immunocompetent man in the absence of prior neurosurgery. *S D Med*. 2016;69(2):71-73.
- Revankar SG, Sutton DA, Rinaldi MG. Primary central nervous system phaeohyphomycosis: a review of 101 cases. *Clin Infect Dis*. 2004;38(2):206-216.
- Wagner K, Springer B, Pires VP, Keller PM. Molecular detection of fungal pathogens in clinical specimens by 18S rDNA

- high-throughput screening in comparison to ITS PCR and culture. *Sci Rep.* 2018;8(1):6964.
22. Akram A, Maley M, Gosbell I, Nguyen T, Chavada R. Utility of 16S rRNA PCR performed on clinical specimens in patient management. *Int J Infect Dis.* 2017;57:144-149.
 23. Culbreath K, Melanson S, Gale J, et al. Validation and retrospective clinical evaluation of a quantitative 16S rRNA gene metagenomic sequencing assay for bacterial pathogen detection in body fluids. *J Mol Diagn.* 2019;21(5):913-923.
 24. Zaffiri L, Abdulmassih R, Boyaji S, Bagh I, Campbell AR, Loehrke ME. Brain abscess induced by propionibacterium acnes in a patient with severe chronic sinusitis. *New Microbiol.* 2013;36:325-329.

How to cite this article: Smith JL, Cruz-Gordillo P, Luiselli G, et al. Spontaneous *Propionibacterium Acnes* abscess with intraventricular rupture in an immunocompetent adult without prior neurosurgical intervention. *Clin Case Rep.* 2022;10:e05216. doi:[10.1002/ccr3.5216](https://doi.org/10.1002/ccr3.5216)