


# eScholarship@UMassChan

## Rat bite fever in a patient with human immunodeficiency virus

Item Type	Case Report
Authors	Bougioukas, Lauren;Vicks, Emily;Hale, Andrew J;Dejace, Jean;Bullis, Sean
Citation	Bougioukas L, Vicks E, Hale AJ, Dejace J, Bullis S. Rat bite fever in a patient with human immunodeficiency virus. IDCases. 2022 Jun 6;29:e01526. doi: 10.1016/j.idcr.2022.e01526. PMID: 35693327; PMCID: PMC9184550.
DOI	<a href="https://doi.org/10.1016/j.idcr.2022.e01526">10.1016/j.idcr.2022.e01526</a>
Journal	IDCases
Rights	© 2022 The Authors. Published by Elsevier Ltd. This is an open access article under the CC BY-NC-ND license ( <a href="http://creativecommons.org/licenses/by-nc-nd/4.0/">http://creativecommons.org/licenses/by-nc-nd/4.0/</a> ).;Attribution-NonCommercial-NoDerivatives 4.0 International
Download date	2025-03-20 19:11:12
Item License	<a href="http://creativecommons.org/licenses/by-nc-nd/4.0/">http://creativecommons.org/licenses/by-nc-nd/4.0/</a>
Link to Item	<a href="https://hdl.handle.net/20.500.14038/52174">https://hdl.handle.net/20.500.14038/52174</a>



## Case report

## Rat bite fever in a patient with human immunodeficiency virus

Lauren Bougioukas<sup>a</sup>, Emily Vicks<sup>b</sup>, Andrew J. Hale<sup>c</sup>, Jean Dejace<sup>c</sup>, Sean Bullis<sup>d,\*</sup><sup>a</sup> Medical student at the Larner College of Medicine at the University of Vermont, Burlington, VT, USA<sup>b</sup> Medical student at the University of Massachusetts Medical School, Worcester, MA, USA<sup>c</sup> Infectious Diseases physician at the University of Vermont Medical Center and Assistant Professor of Medicine at Larner College of Medicine at the University of Vermont, Burlington, VT, USA<sup>d</sup> University of Vermont Medical Center, Burlington, VT and Assistant Professor of Medicine at Larner College of Medicine at the University of Vermont, Burlington, VT, USA

## ARTICLE INFO

## Keywords:

Rat bite fever

*Streptobacillus moniliformis*

HIV

RBF

Human immunodeficiency virus

## ABSTRACT

The authors report the case of a 45-year-old male with history of human immunodeficiency virus who presented unresponsive and with injuries to his hands after spending a night on a lakeside beach. During his hospitalization, he developed a fever with arthralgias and was initially thought to have calcium pyrophosphate dihydrate crystal deposition disease before a diagnosis of Rat Bite Fever was ultimately discovered. He was successfully treated with six-weeks of ceftriaxone. The authors discuss the epidemiology, diagnosis, treatment, and prognosis of Rat Bite Fever.

## Introduction

Rat Bite Fever (RBF) is rare zoonotic infection caused by transmission of *Streptobacillus moniliformis* or *Spirillum minus* often from the nasopharyngeal flora of rats or other rodents [1]. Diagnosis can be challenging as it often presents with non-specific, flu-like symptoms including fever, arthralgias, and rash [1–5]. Furthermore, *S. moniliformis* is a fastidious bacterium which makes definitive diagnosis difficult [2, 6]. An untreated infection can lead to mortality with rates around 7–13%; however, infants and those who develop endocarditis have mortality rates around 50% [1,3,4,7,8]. RBF can be successfully treated with penicillin as well as a wide variety of other antimicrobial agents [1, 3,9]. Herein, we report a case of RBF in a male with human immunodeficiency virus, who was successfully treated with six-weeks of ceftriaxone.

## Case presentation

A 45-year-old male with human immunodeficiency virus (HIV) on antiretroviral therapy presented to our emergency department in April, after he was found unresponsive, hypothermic, and with injuries to his hands following a night of binge alcohol use on a local lakeside beach. Medical history was significant for opiate use disorder with remote injection drug use, alcohol dependence complicated by withdrawal

seizures, treated hepatitis C virus, and shingles complicated by post-herpetic neuralgia. Socially, he had lived throughout the contiguous United States prior to moving to Vermont and was sexually active with female partners.

On initial presentation, temperature was 36.7 °C, blood pressure 138/81 mmHg, heart rate 116 beats per minute, and the respiratory rate was 16 breaths/minute. Exam was notable for dried blood on his hands and clothes. He had severe, non-radiating, epigastric abdominal pain, an ovoid skin tear on the right second extensor proximal interphalangeal joint, and a laceration on the tip of the right second digit. All extremities were cool to touch.

Laboratory testing revealed a white blood cell count (WBC) of  $15 \times 10^3$  cells/uL (baseline  $6 \times 10^3$  cells/uL), aspartate transaminase of 63 U/L (baseline 36 U/L), creatine kinase of 1087 U/L, and lactate of 5 mmol/L (baseline 2.0 mmol/L). Computed tomography (CT) imaging of the head, abdomen, pelvis, and cervical spine were unremarkable. Nasopharyngeal polymerase chain reaction (PCR) assays for COVID-19, influenza, and respiratory syncytial virus were negative. He was admitted to the hospital for supportive care and management of presumed rhabdomyolysis.

On hospital day 4, he developed a new fever to 40 °C, accompanied by rigors, widespread myalgias, and headache. Labs at this time showed WBC  $6.6 \times 10^3$  cells/uL, hemoglobin 17.5 gm/dL (baseline 14 gm/dL), platelets 125,000/ $\mu$ L (baseline 280,000/uL), lactate 1.6 mmol, and C-

\* Correspondence to: University of Vermont Medical Center, Infectious Disease Unit, 111 Colchester Avenue, Mailstop 115 SM2, Burlington, VT 05401, USA.  
E-mail address: [Sean.Bullis@UVMhealth.org](mailto:Sean.Bullis@UVMhealth.org) (S. Bullis).

reactive protein (CRP) of 118 mg/L. High spiking fevers continued unabated over the ensuing 5 days. Extensive infectious work-up, including blood cultures, Lyme serology, syphilis serology, blood parasite exams, repeat COVID-19 testing, hepatitis A serology, Epstein-Barr virus serology, parvovirus-19 serology, blastomyces and histoplasma urine antigens, Legionella urine antigen, Chlamydia and Gonorrhea Nucleic Acid Amplification Test (NAAT) of urine, transthoracic echocardiogram, and lumbar puncture were all unremarkable or negative. A therapeutic trial of doxycycline was initiated on hospital day 8 given the possibility of anaplasmosis but was discontinued on hospital day 9 after anaplasmosis PCR returned negative. On hospital day 9, worsening polyarthralgia that was most pronounced in the left knee and right wrist prompted rheumatology to perform arthrocentesis. Synovial fluid analysis of the left knee consisted of WBC 40,740 cells/uL (83% neutrophils, 1% lymphocytes, and 16% monocytes), RBC < 10,000 cells/uL, and the presence of calcium pyrophosphate (CPP) crystals; while that of the right wrist consisted of WBC 61,670 cells/uL (84% neutrophils, 4% lymphocytes, 12% monocytes), RBC 17,000 cells/uL, and the presence of CPP crystals. Both analyses were consistent with a diagnosis of calcium pyrophosphate dihydrate crystal deposition disease, prompting institution of a prednisone taper starting at 40 mg daily. He improved clinically with resolution of fever and was discharged by hospital day 11.

Two-weeks after discharge, he had recrudescence of fever accompanied by new right knee and left wrist pain. He presented to his local community hospital where he was started on piperacillin-tazobactam and taken for arthroscopic washout of the right knee. Operative cultures ultimately grew rare gram-negative rods, later identified on Matrix-assisted laser desorption/ionization-time of flight mass spectrometry (MALDI-TOF MS) as *Streptobacillus moniliformis* (Fig. 1), one of the causative agents of RBF. He was transitioned to ceftriaxone 2 g IV every day. Following six weeks of this therapy, he had full resolution of all symptoms.

## Discussion

First coming to widespread attention in 1926 during a foodborne outbreak in Haverhill, Massachusetts, *S. moniliformis* is now more commonly recognized as the causative agent of Rat Bite Fever (RBF) in North America [1,8,10]. To date, three large outbreaks of Haverhill fever have been described. As the name suggests, RBF is acquired chiefly via direct inoculation of *S. moniliformis* via bites and is characterized by the triad of relapsing fever, migratory arthralgias, and rash. When the bacterium is acquired via oral ingestion (Haverhill Fever), there is in addition a preponderance of pharyngitis and vomiting [1,8,10]. In Asia, the causative agent of RBF is most often *Spirillum minus*, but other species have been described, and the syndrome of RBF has been recognized worldwide [1,11]. Untreated cases are associated with mortality rates

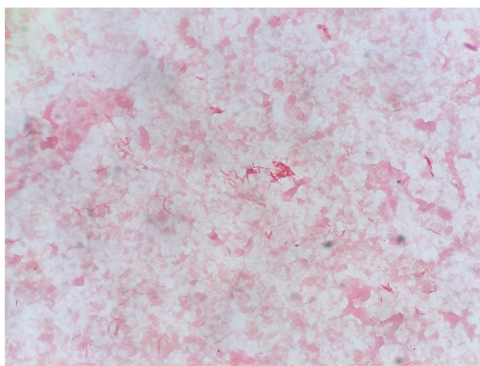


Fig. 1. Gram stain of *Streptobacillus moniliformis*. Culture taken from the patient's right knee joint synovial fluid.

that range from 7% to 13% [10], but among infants and those with concomitant endocarditis, rates may exceed 50% [1,3,4,7,8].

Owing to its rarity and status as a non-reportable illness in the United States, RBF likely remains an occult public health threat, as rats cause an estimated 20,000 bites annually [1,4,10]. Because *S. moniliformis* is a resident colonizer of nasopharyngeal flora in rats (as well as other small rodents such as mice, guinea pigs, and squirrels), *S. moniliformis* can be transmitted to humans via bites, scratches, or licks [1]. A rise in incidence exceeding two-fold between 1990 and 1998 was postulated to be due to an increase in rodent ownership as domesticated pets and improved identification techniques [8].

Clinically, RBF often follows a biphasic course, with flu-like symptoms predominating early followed by migratory asymmetric polyarthralgia and rash that may be maculopapular, petechial, or purpuric, can involve the palms and soles, and spreads centripetally [1–5,12]. RBF may cause both arthralgias associated with RBF and septic arthritis, with the latter less commonly observed with concomitant bacteremia [13]. The knee is the most common joint affected in 58.3% of adult cases, but among pediatric cases, the hips are more commonly implicated [7,13,14].

Given its rarity, non-specific symptoms, and often overlooked antecedent epidemiologic risk factors, it is perhaps not surprising that clinicians initially consider RBF in less than 50% of patients presenting with a compatible syndrome [8]. Left untreated, RBF may be complicated by endocarditis (particularly previously abnormal or prosthetic valves), myopericarditis, pneumonia, osteomyelitis, and abscesses that have been described in almost all organ systems, including the central nervous system [1,2,10,15–17].

Although RBF is often suspected clinically, diagnosis may be aided by direct visualization of pleomorphic bacillary organisms from a sterile space [18]. Definitive diagnosis can be extremely challenging owing to the fastidious nature of this organism, and, as in the present case, often relies upon culture and molecular identification via MALDI-TOF MS [2,6]. Culture yield is increased with use of media that does not contain sodium polyanethol sulfonate and as such, the microbiology lab should be alerted whenever this entity is on the differential [12].

In our patient, concurrent HIV complicated diagnosis and management, and there have been a couple other cases reported in the literature [19,20]. Chean et al. (2012) described a case of culture-negative *S. moniliformis* septic arthritis in a 30-year-old male with advanced HIV/AIDS [19]. The patient presented with one month of non-specific symptoms including intermittent fever, myalgias, weight loss. On his third hospital day, he developed right knee pain. Arthrocentesis of the synovial fluid analysis was negative. A week later, it was revealed that the patient had been bitten by one of his pet rats about one month prior. DNA from the original synovial fluid sample was then analyzed using MicroSeq 500 system and found to be consistent with *S. moniliformis*. The patient clinically improved by completing a 6-week course of IV benzylpenicillin, followed by 4 weeks of oral doxycycline. Another case of RBF in a HIV-positive patient was described by Rordorf et al. [20]. A 37-year-old HIV-positive male and with a history of IV drug use presented with a few months of fever and chills, and a week of pain and swelling in his joints. On his second hospital day, he developed a fever of 38.8 °C and shaking chills. He was ultimately diagnosed with *S. moniliformis* endocarditis of the mitral valve. The patient was treated with 3-weeks of ceftriaxone, 2-weeks of gentamicin, and 1-week of penicillin, which lead to resolution of fever and joint swelling, and a significant reduction in the size of his mitral vegetation [20].

Diagnosis of RBF in HIV patients can be challenging for several reasons. In both cases illustrated above, as well as the case presented here, none of the patients had a rash, which is characteristically part of the RBF triad of symptoms. One possible theory for the absence of rash in this population may be due to a blunted immune response that can occur in patients with abnormal T-cell function. For example, there have been reports of measles occurring in the absence of a rash in patients with history of HIV and giant-cell pneumonia [21,22]. Another reason why

diagnosis was difficult in our patient was use of corticosteroids for concomitant CPPD, which likely contributed to his dramatic defervescence. However, it is also possible that this may have been related to the biphasic natural history of RBF.

Additionally, diagnosis can be difficult in HIV patients due to similar symptomatology to other etiologies that can occur in this population. RBF symptoms can mimic those seen in AIDS-associated arthropathy or acute HIV syndrome [20]. Septic arthritis and endocarditis, with *Staphylococcus aureus* and *Candida albicans* as common causative agents, can occur in individuals with a history of IV drug use [19]. Other infectious etiologies to keep on the differential in HIV-positive patients include syphilis; bacillary angiomatosis; *Neisseria gonorrhoeae*; pneumococcus; parvovirus B19; fungal infections such as cryptococcus, histoplasmosis, or blastomycosis; and Kaposi sarcoma.

Despite the challenges of accurate diagnosis, RBF remains exquisitely susceptible to penicillin, but ceftriaxone, tetracyclines, clindamycin, and erythromycin have also been used successfully [2,4,5,23]. Dendle et al. (2006) found no reported failure of antimicrobial treatment of RBF, irrespective of the antimicrobial therapy used [1,3,9]. Furthermore, uncomplicated RBF is generally treated for two weeks, but concomitant endocarditis requires a longer course, and based on limited clinical experience, an aminoglycoside may be added [6].

In summary, RBF should be considered in the differential for relapsing fever syndromes. To aid in diagnosis, both a thorough social history to screen for animal exposures and a comprehensive skin exam to evaluate for scratches or bites are paramount. Furthermore, in patients with HIV, the diagnosis can be difficult due to its similar symptomatology to other syndromes and infectious etiologies that can occur in this population.

#### Funding

None.

#### CRediT authorship contribution statement

**Lauren Bougioukas:** Writing and editing of manuscript. **Emily Vicks:** Writing and editing of manuscript. **Andrew J. Hale:** Writing and editing of manuscript. **Jean DeJace:** Writing and editing of manuscript. **Sean Bullis:** Clinical care, Writing and editing of manuscript.

#### Authorship verification

All co-authors have seen and agree with the contents of the manuscript and have contributed significantly to the work.

#### Conflict of interest statement

None of the authors report any conflicts of interest.

#### References

- [1] Akter R, Boland P, Daley P, Rahman P, Al Ghanim N. Rat bite fever resembling rheumatoid arthritis. *Can J Infect Dis Med Microbiol* 2016;2016:7270413.
- [2] Shadrin IY, Albitar HAH, Paim AC, Issa M, Wilson WR. Migratory polyarthralgias and skin rash: rat bite fever with a positive anti-cyclic citrullinated peptide. *Mayo Clin Proc Innov Qual Outcomes* 2020;4(2):223–7.
- [3] Dendle C, Woolley IJ, Korman TM. Rat-bite fever septic arthritis: illustrative case and literature review. *Eur J Clin Microbiol Infect Dis* 2006;25(12):791–7.
- [4] Gaastra W, Boot R, Ho HT, Lipman LJ. Rat bite fever. *Vet Microbiol* 2009;133(3):211–28.
- [5] McKee G, Pawarchuk J. Rat-bite fever. *CMAJ* 2013;185(15):1346.
- [6] Torres-Miranda D, Moshgriz M, Siegel M. Streptococcus moniliformis mitral valve endocarditis and septic arthritis: the challenges of diagnosing rat-bite fever endocarditis. *Infect Dis Rep* 2018;10(2):7731.
- [7] Kanechorn Na Ayuthaya R, Niumpadit N. Rat-bite fever presenting with rash and septic arthritis. *J Med Assoc Thai* 2005;88(Suppl 3):S247–51.
- [8] Graves MH, Janda JM. Rat-bite fever (Streptococcus moniliformis): a potential emerging disease. *Int J Infect Dis* 2001;5(3):151–5.
- [9] Kammerer T, Lesmeister T, Wollenberg A, French LE, Strobel E, Reinholz M. Rat bite fever, a diagnostic challenge: case report and review of 29 cases. *J Dtsch Dermatol Ges* 2021;19(9):1283–7.
- [10] Elliott SP. Rat bite fever and Streptococcus moniliformis. *Clin Microbiol Rev* 2007;20(1):13–22.
- [11] Onodera H, Uekita H, Watanabe T, Taira K, Watanabe C, Saito H, et al. Rat-bite fever due to streptococcus moniliformis in a patient without bite history: an unexpected cause of consciousness disturbance. *Jpn J Infect Dis* 2020;73(1):85–7.
- [12] John EB, Raphael D, Martin JB. Mandell, Douglas, and Bennett's Principles and Practice of Infectious Diseases E-Book. Philadelphia, PA: Elsevier.; 2020.
- [13] Wang TK, Wong SS. Streptococcus moniliformis septic arthritis: a clinical entity distinct from rat-bite fever? *BMC Infect Dis* 2007;7:56.
- [14] Hadvani T, Vallejo JG, Dutta A. Rat bite fever: variability in clinical presentation and management in children. *Pedia Infect Dis J* 2021;40(11):e439–42.
- [15] Frederick AR, Fowler BC, Kolluri R. Images in Vascular Medicine. Rat bite fever: A rare case of critical limb ischemia. *Vasc Med* 2019;24(5):465–6.
- [16] Adams SH, Mahapatra R. Rat bite fever with osteomyelitis and discitis: case report and literature review. *BMC Infect Dis* 2021;21(1):479.
- [17] Pena E, Jordao S, Simoes MJ, Oleastro M, Neves I. A rare cause of vertebral osteomyelitis: the first case report of rat-bite fever in Portugal. *Rev Soc Bras Med Trop* 2019;53:e20190328.
- [18] Ojukwu IC, Christy C. Rat-bite fever in children: case report and review. *Scand J Infect Dis* 2002;34(6):474–7.
- [19] Chean R, Stefanski DA, Woolley IJ, Francis MJ, Korman TM. Rat bite fever as a presenting illness in a patient with AIDS. *Infection* 2012;40(3):319–21.
- [20] Rordorf T, Zuger C, Zbinden R, von Graevenitz A, Pirovino M. Streptococcus moniliformis endocarditis in an HIV-positive patient. *Infection* 2000;28(6):393–4.
- [21] Enders JF, Mc CK, Mitus A, Cheatham WJ. Isolation of measles virus at autopsy in cases of giant-cell pneumonia without rash. *N Engl J Med* 1959;261:875–81.
- [22] Markowitz LE, Chandler FW, Roldan EO, Saldana MJ, Roach KC, Hutchins SS, et al. Fatal measles pneumonia without rash in a child with AIDS. *J Infect Dis* 1988;158(2):480–3.
- [23] Freels LK, Elliott SP. Rat bite fever: three case reports and a literature review. *Clin Pediatr (Philo)* 2004;43(3):291–5.