

eScholarship@UMassChan

BRAF and epithelial-mesenchymal transition in papillary thyroid carcinoma - challenging the roles of Snail and E-Cadherin

Item Type	Journal Article
Authors	Mitchell, Brendon;Leone, Dominick;Yang, Shi;Khan, Ashraf;Mahalingam, Meera;Dhingra, Jagdish
Citation	Am J Transl Res. 2016 Nov 15;8(11):5076-5086. eCollection 2016. Link to article on publisher's website
Rights	AJTR Copyright © 2016. Publisher PDF posted as allowed by the publisher's author rights policy at http://www.ajtr.org/guidelines.html .
Download date	2026-03-08 23:45:00
Item License	http://creativecommons.org/licenses/by-nc/4.0/
Link to Item	https://hdl.handle.net/20.500.14038/40193

Original Article

BRAF and epithelial-mesenchymal transition in papillary thyroid carcinoma - challenging the roles of Snail and E-Cadherin?

Brendon Mitchell¹, Dominick Leone², Shi Yang³, Ashraf Khan⁴, Meera Mahalingam⁵, Jagdish Dhingra⁶

¹University of Florida College of Medicine, Gainesville, FL, USA; ²Division of Graduate Medical Sciences, ³Department of Pathology, Boston University School of Medicine, Boston, MA, USA; ⁴Department of Pathology, University of Massachusetts Medical School, Worcester, MA, UK; ⁵Dermatopathology Section, Department of Pathology and Lab Medicine (113), VA Consolidated Laboratories, 1400 VFW PKWY, West Roxbury, MA 02132, USA; ⁶ENT Specialists, Inc., 825 Washington St # 310, Norwood, MA 02062, UK

Received August 31, 2016; Accepted September 27, 2016; Epub November 15, 2016; Published November 30, 2016

Abstract: Objective: In papillary thyroid carcinoma (PTC), while the role of BRAF is well established, the contribution of BRAF to epithelial-mesenchymal transition is not. Study design/Setting: To elucidate the relationship between BRAF, surrogates of epithelial-mesenchymal transition (Snail, E-cadherin) and established histopathologic prognosticators in papillary thyroid carcinoma. Subjects/methods: In this IRB approved cross-sectional study, 50 cases of archived annotated PTC samples were retrieved and immunohistochemically stained for Snail and E-cadherin protein. A semi-quantitative scoring system (incorporating proportion and intensity) was utilized. Results: Snail and E-cadherin expression were noted in 44% and 84% of BRAF mutant and, in 29% and 95% of BRAFWT samples, respectively. No statistically significant correlations were noted between Snail, E-cadherin and histopathologic prognosticators. However, a trend was noted between Snail expression and tumor size <5 cm (P=0.07). Statistically significant differences between BRAF mutant and BRAFWT samples were noted in the following groups: conventional (68% vs. 5%) and tall cell (32% vs. 0%) histopathologic variants, extrathyroidal extension (32% vs. 5%), infiltrative growth pattern (80% vs. 48%), presence of desmoplasia (72% vs. 29%), psammoma bodies (48% vs. 10%), and cystic change (32% vs. 5%). Among follicular variant of papillary thyroid carcinoma compared to BRAF mutant samples, BRAFWT samples were more commonly of the encapsulated variety (52% vs. 4%), and microcarcinomas (29% vs. 0%) (P<0.001 and =0.007, respectively). Conclusion: Our findings, supporting the utility of BRAF as a putative therapeutic target in PTC, suggest that the interaction between BRAF and epithelial-mesenchymal transition in papillary thyroid carcinoma is not through induction of the Snail/E-cadherin pathway.

Keywords: BRAF, Snail, E-cadherin, epithelial-mesenchymal transition, papillary thyroid carcinoma

Introduction

Papillary thyroid cancer accounts for 80% of all thyroid cancers, making it significantly more common than poorly differentiated and follicular thyroid carcinomas [1]. Over the last century, the incidence of papillary thyroid carcinoma has risen over 15 fold in women and 1.2 fold in men [1]. Interestingly, the incidence of follicular and poorly differentiated thyroid carcinomas has remained relatively stable over this time [1]. In addition to an increase in primary tumors, there has been an increase in the incidence of regional and distant metastases by papillary

thyroid carcinoma, increasing the need for improving our understanding of the pathogenesis and identifying effective, targeted treatments [2].

One such molecule of interest is the BRAF protein, which has been tied to poor patient outcome in numerous malignancies. In papillary thyroid carcinoma, the presence of a BRAF mutation has been established as a prognosticator of poor clinical outcome [3-11]. The role of BRAF and dysregulation of the MAPK pathway in papillary thyroid carcinoma cell proliferation and survival has been well established [12].

BRAF and epithelial-mesenchymal transition in papillary thyroid carcinoma

Table 1. Correlation of Snail with E-cadherin expression, BRAF status, and established histopathologic prognosticators

Histopathologic Prognosticator	n (46 total)	Snail Expression		Significance (<i>p</i> -value)
		Present (n=17)	Absent (n=29)	
Gender				
Male	12 (26.1)	5 (29.4)	7 (24.1)	0.25 ^a
Female	34 (73.9)	12 (70.6)	22 (75.9)	
E-Cadherin Intensity				
Present	41 (89.1)	16 (94.1)	25 (86.2)	0.64
Not Present	5 (10.9)	1 (5.9)	4 (13.8)	
BRAF Status				
Mutant	25 (54.4)	11 (64.7)	14 (48.3)	0.28
Wild-type	21 (45.6)	6 (35.3)	15 (51.7)	
Primary Tumor Size				
<5 cm	41 (89.1)	17 (100.0)	24 (82.8)	0.07 ^b
≥5 cm	5 (10.9)	0 (0.0)	5 (17.24)	
Conventional Variant				
Present	18 (39.1)	8 (47.1)	10 (34.5)	0.40
Not Present	28 (60.9)	9 (52.9)	19 (65.5)	
Encapsulated Follicular Variant				
Present	12 (26.1)	2 (11.8)	10 (34.5)	0.16 ^a
Not Present	34 (73.9)	15 (88.2)	19 (65.5)	
Infiltrative Follicular Variant				
Present	14 (30.4)	4 (23.5)	10 (34.5)	0.52 ^a
Not Present	32 (69.6)	13 (76.5)	19 (65.5)	
Papillary Microcarcinoma				
Present	6 (13.0)	2 (11.8)	4 (13.8)	1.00 ^a
Not Present	40 (87.0)	15 (88.2)	25 (86.2)	
Tall Cell Variant				
Present	6 (13.0)	4 (23.5)	2 (6.9)	0.17 ^a
Not Present	40 (87.0)	13 (76.5)	27 (93.1)	
Angioinvasion				
Present	6 (13.0)	3 (17.7)	3 (10.3)	0.66 ^a
Not Present	40 (87.0)	14 (82.3)	26 (89.7)	
Multicentricity				
Present	11 (23.9)	3 (17.7)	8 (27.6)	0.5 ^a
Not Present	35 (76.1)	14 (82.3)	21 (72.4)	
Extrathyroidal Extension				
Present	9 (19.6)	5 (29.4)	4 (13.8)	0.26 ^a
Not Present	37 (80.4)	12 (70.6)	25 (86.2)	
Growth Pattern				
Pushing	16 (34.8)	5 (29.4)	11 (37.9)	0.56
Infiltrative	30 (65.2)	12 (70.6)	18 (62.1)	
Desmoplasia				
Present	24 (52.2)	11 (64.7)	13 (44.8)	0.19
Not Present	22 (47.8)	6 (35.3)	16 (55.2)	
Psammoma Body				
Present	14 (30.4)	7 (41.2)	7 (24.1)	0.23
Not Present	32 (69.6)	10 (58.8)	22 (75.9)	

Lesser understood, but becoming more apparent, is the contribution of BRAF to the epithelial to mesenchymal transition, necessary for malignant carcinoma cells to detach from their primary epithelial site and metastasize [13]. One mechanism by which mutations to the BRAF protein is believed to contribute to the epithelial to mesenchymal transition in papillary thyroid carcinoma is through upregulation of the Snail, a zinc finger transcriptional factor, generated from the proto-oncogene *SNAI1* [14]. Snail expression is upregulated by NFκB, which has affinity for the *SNAI1* promoter [15]. Once transcribed, Snail translocates to the nucleus, where it binds E-box, which is an E-cadherin promoter region [16]. Binding to E-box promotes downregulation of E-cadherin, allowing for the detachment of cells from the epithelium in a process known as the epithelial-mesenchymal transition [14].

Given these associations and the relative paucity of literature on the interplay between these molecules, we sought to elucidate the relationship between BRAF, Snail, E-cadherin and established histopathologic prognosticators in papillary thyroid carcinoma.

BRAF and epithelial-mesenchymal transition in papillary thyroid carcinoma

Tumor Associated Lymphocytes				
Present	8 (17.4)	4 (23.5)	4 (13.8)	0.44
Not Present	38 (82.6)	13 (76.5)	25 (86.2)	
Cystic Changes				
Present	9 (19.6)	5 (29.4)	4 (13.8)	0.26
Not Present	37 (80.4)	12 (70.6)	25 (86.2)	
Sclerosis				
Present	25 (54.4)	9 (52.9)	16 (55.2)	0.88
Not Present	21 (45.6)	8 (47.1)	13 (44.8)	

^a*p*-value derived using fisher-exact. ^b0.5 added to all cells and fisher exact used to derive *p*-value. Note: For comparison, a chi-square derived using the more conservative Yates to correct for continuity yielded *P*=0.26 for primary tumor size.

Table 2. Correlation of E-cadherin with BRAF status and established histopathologic prognosticators

Histopathologic Prognosticator	n (46 total)	Snail Expression		Significance (<i>p</i> -value)
		Present (n=41)	Absent (n=5)	
Gender				
Male	12 (26.1)	11 (26.8)	1 (20.0)	1.00 ^a
Female	34 (73.9)	30 (73.2)	4 (80.0)	
BRAF Status				
Mutant	25 (54.4)	21 (51.2)	4 (80.0)	0.36 ^a
Wild-type	21 (45.6)	20 (48.8)	1 (20.0)	
Primary Tumor Size				
<5 cm	41 (89.1)	37 (90.2)	4 (80.0)	0.45 ^a
≥5 cm	5 (10.9)	4 (9.8)	1 (20.0)	
Conventional Variant				
Present	18 (39.1)	16 (39.0)	2 (40.0)	1.00 ^a
Not Present	28 (60.9)	25 (61.0)	3 (60.0)	
Encapsulated Follicular Variant				
Present	12 (26.1)	12 (29.3)	0 (0.0)	0.31 ^b
Not Present	34 (73.9)	29 (70.7)	5 (100.0)	
Infiltrative Follicular Variant				
Present	14 (30.4)	12 (29.3)	2 (40.0)	0.63 ^a
Not Present	32 (69.6)	29 (70.7)	3 (60.0)	
Papillary Microcarcinoma				
Present	6 (13.0)	5 (12.2)	1 (20.0)	0.52 ^a
Not Present	40 (87.0)	36 (87.8)	4 (80.0)	
Tall Cell Variant				
Present	6 (13.0)	5 (12.2)	1 (20.0)	0.52 ^a
Not Present	40 (87.0)	36 (87.8)	4 (80.0)	
Angioinvasion				
Present	6 (13.0)	6 (14.6)	0 (0.0)	Not Available
Not Present	40 (87.0)	35 (85.4)	5 (100.0)	
Multicentricity				
Present	11 (23.9)	11 (26.8)	0 (0.0)	0.31 ^b
Not Present	35 (76.1)	30 (73.2)	5 (100.0)	
Extrathyroidal Extension				

Materials and methods

Sample selection

In this institutional review board approved project, annotated cases with a diagnosis papillary thyroid carcinoma (n=50) were retrieved from the archives of the Department of Pathology, Boston Medical Center, MA, USA. Cases were selected such that the cohort contained 25 BRAF-mutant and 25 BRAF wild-type samples. Histopathologic sections of all cases were reviewed by 2 board-certified pathologists (initial sign-out on all by a Board certified pathologist; cases were then re-reviewed, and the diagnoses confirmed by MM and AK). All patient data were de-identified.

DNA analyses

DNA was extracted by proteinase K digestion and boiling. For sequencing analysis, AS-PCR was performed to detect V600E (GTG>GAG) and V600K (GTG>AAG) mutations. The sequencing results were analyzed with ABI DNA Sequencing Analysis Software version 6. Appropriate controls were included with each batch of PCR sequencing reactions.

Immunohistochemistry

Immunohistochemistry was performed on 4

BRAF and epithelial-mesenchymal transition in papillary thyroid carcinoma

Present	9 (19.6)	9 (21.9)	0 (0.0)	0.32 ^b
Not Present	37 (80.4)	32 (78.1)	5 (100.0)	
Growth Pattern				
Pushing	16 (34.8)	15 (36.6)	1 (20.0)	0.64 ^a
Infiltrative	30 (65.2)	26 (63.4)	4 (80.0)	
Desmoplasia				
Present	24 (52.2)	22 (53.7)	2 (40.0)	0.66 ^a
Not Present	22 (47.8)	19 (46.3)	3 (60.0)	
Psammoma Body				
Present	14 (30.4)	13 (31.7)	1 (20.0)	1.00 ^a
Not Present	32 (69.6)	28 (68.3)	4 (80.0)	
Tumor Associated Lymphocytes				
Present	8 (17.4)	8 (19.5)	0 (0.0)	0.57 ^b
Not Present	38 (82.6)	33 (80.5)	5 (100.0)	
Cystic Changes				
Present	9 (19.6)	9 (21.9)	0 (0.0)	0.32 ^b
Not Present	37 (80.4)	32 (78.1)	5 (100.0)	
Sclerosis				
Present	25 (54.4)	24 (58.5)	1 (20.0)	0.16
Not Present	21 (45.6)	17 (41.5)	4 (80.0)	

^a*p*-value derived using fisher-exact. ^b0.5 added to all cells and fisher exact used to derive *p*-value. Note: For comparison, a chi-square derived using the more conservative Yates to correct for continuity yielded *P*=0.54 for encapsulated follicular variant, *P*=0.61 for multicentricity, *P*=0.79 for extrathyroidal extension, *P*=0.89 for tumor associated lymphocytes, and *P*=0.79 for cystic changes.

Table 3. Correlation of BRAF status with established histopathologic prognosticators

Histopathologic Prognosticator	n (46 total)	BRAF Status		Significance (<i>p</i> -value)
		Mutant (n=25)	Wild-Type (n=21)	
Gender				
Male	12 (26.1)	6 (24.0)	6 (28.6)	0.73
Female	34 (73.9)	19 (76.0)	15 (71.4)	
Primary Tumor Size				
<5 cm	41 (89.1)	24 (96.0)	17 (80.9)	0.16
≥5 cm	5 (10.9)	1 (4.0)	4 (19.1)	
Conventional Variant				
Present	18 (39.1)	17 (68.0)	1 (4.8)	<0.0001 ^a
Not Present	28 (60.9)	8 (32.0)	20 (95.2)	
Encapsulated Follicular Variant				
Present	12 (26.1)	1 (4.0)	11 (52.4)	<0.0001 ^a
Not Present	34 (73.9)	24 (96.0)	10 (47.6)	
Infiltrative Follicular Variant				
Present	14 (30.4)	6 (24.0)	8 (38.1)	0.30
Not Present	32 (69.6)	19 (76.0)	13 (61.9)	
Papillary Microcarcinoma				
Present	6 (13.0)	0 (0.0)	6 (28.6)	0.007 ^b
Not Present	40 (87.0)	25 (100.0)	15 (71.4)	
Tall Cell Variant				

µm formalin-fixed, paraffin-embedded sections using a commercially available mouse monoclonal antibody for e-cadherin (36 Ventana, Tucson, AZ, USA) at a dilution of 1:50 and a rabbit polyclonal antibody for SNAIL1 (ab180714 Abcam, Cambridge, MA, USA) at a dilution of 1:150. Target retrieval using Reaction Buffer pH 7.5 (Ventana) was performed at 97°C for 30 minutes. The slides were treated with dual endogenous enzyme block (DAKO) before primary antibody staining. For E-cadherin, samples were incubated with the primary antibody for 32 minutes at room temperature. For Snail, samples were incubated with primary antibody overnight at 4°C. Color development and contrast were achieved using DAB and hematoxylin, respectively. All steps were carried out using the Ventana Benchmark XT (Ventana).

For all immunohistochemical stains used in the study appropriate positive and negative controls were included with each run. All stained slides were reviewed and scored by two authors (BM and MM) in a blinded fashion with respect to each other's scores. Any disagreements were reviewed together to achieve a consensus score. Internal positive

BRAF and epithelial-mesenchymal transition in papillary thyroid carcinoma

Present	6 (13.0)	6 (24.0)	0 (0.00)	0.02 ^b
Not Present	40 (87.0)	19 (76.0)	21 (100.0)	
Angioinvasion				
Present	6 (13.0)	3 (12.0)	3 (14.3)	1.00 ^a
Not Present	40 (87.0)	22 (88.0)	18 (85.7)	
Multicentricity				
Present	11 (23.9)	8 (32.0)	3 (14.3)	0.19 ^a
Not Present	35 (76.1)	17 (68.0)	18 (85.7)	
Extrathyroidal Extension				
Present	9 (19.6)	8 (32.0)	1 (4.8)	0.03 ^a
Not Present	37 (80.4)	17 (68.0)	20 (95.2)	
Growth Pattern				
Pushing	16 (34.8)	5 (20.0)	11 (52.4)	0.03 ^a
Infiltrative	30 (65.2)	20 (80.0)	10 (47.6)	
Desmoplasia				
Present	24 (52.2)	18 (72.0)	6 (28.6)	0.003
Not Present	22 (47.8)	7 (28.0)	15 (71.4)	
Psammoma Body				
Present	14 (30.4)	12 (48.0)	2 (9.5)	0.009 ^a
Not Present	32 (69.6)	13 (52.0)	19 (90.5)	
Tumor Associated Lymphocytes				
Present	8 (17.4)	6 (24.0)	2 (9.5)	0.26 ^a
Not Present	38 (82.6)	19 (76.0)	19 (90.5)	
Cystic Changes				
Present	9 (19.6)	8 (32.0)	1 (4.8)	0.03 ^a
Not Present	37 (80.4)	17 (68.0)	20 (95.2)	
Sclerosis				
Present	25 (54.4)	12 (48.0)	13 (61.9)	0.35
Not Present	21 (45.6)	13 (52.0)	8 (38.1)	

^ap-value derived using fisher-exact. ^b0.5 added to all cells and fisher exact used to derive p-value. Note: For comparison, a chi-square derived using the more conservative Yates to correct for continuity yielded P=0.02 for papillary microcarcinoma and P=0.07 for tall cell variant.

controls were used for all stains. For e-cadherin, membranous staining of normal follicular cells was used as an internal positive control. For Snail, normal thyroid follicle colloid was used as an internal positive control.

For E-cadherin and Snail, a semi-quantitative scoring system was utilized with the following cut-offs: 1=0-10%, 2≥10-50% and 3≥50%. In addition, each sample was given a score of intensity graded as weak (1), moderate (2), and strong (3) as compared to internal positive controls. These two scores were added up and, for purposes of statistical analyses, cases with a composite score of 4 or more were considered positive. For e-cadherin, statistical analysis was also performed using the intensity score

alone, as samples often demonstrated variable staining within a given tumor specimen.

Of note, four BRAFWT samples did not demonstrate observable lesional tissue and could not be used for immunohistochemical analyses.

Statistical analysis

To ascertain the clinical correlates of BRAF mutational status, Snail expression, and E-cadherin expression, separate (bivariate analyses) chi-square tests of independence were used if expected cell counts were greater than 5. However, for cases where cross-tabulation resulted in less than cells <5, Fisher exact method was used, unless any one cell was zero. In those cases where stratification led to a frequency of zero, 0.5 was added to all cells using a well-described

algorithm. To help ensure this did not lead to a type-I or type-II error, the more conservative Yates Correction was applied, and results noted in the footer of **Tables 1-3**.

Results

Snail expression does not correlate with BRAF status, E-cadherin expression, and established histopathologic prognosticators in papillary thyroid carcinoma

Overall, positive Snail expression was noted in 37% (17/46) of all samples; 44% (11/25) of BRAF mutant and 29% (6/21) of BRAFWT. No statistically significant correlations were noted between Snail and established histopathologic prognosticators; however, compared to sam-

BRAF and epithelial-mesenchymal transition in papillary thyroid carcinoma

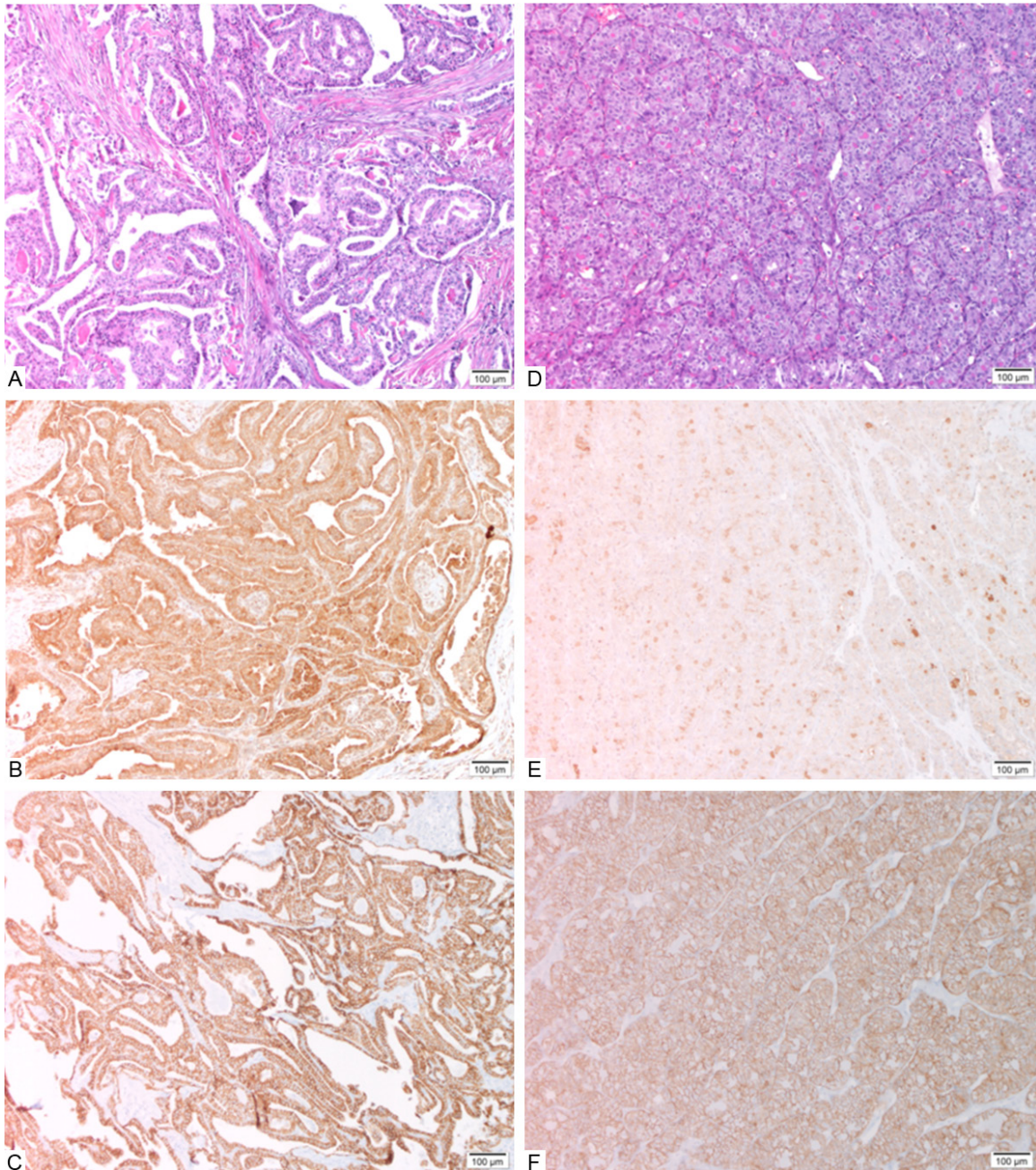


Figure 1. Representative examples of cases from study with positive immunohistochemical staining for Snail and E-cadherin (Case 2, A-C) and negative immunohistochemical staining for Snail and positive immunohistochemical staining for E-cadherin (Case 27, D-F). A = H&E; B = Positive immunohistochemical staining for Snail; C = Positive immunohistochemical staining for E-cadherin. D = H&E; E = Negative immunohistochemical staining for Snail; F = Positive immunohistochemical for E-cadherin.

ples with absent snail expression, tumors demonstrating Snail were more commonly less than 5 cm (100% vs. 83%, 17/17 vs. 24/29, $P=0.07$). E-cadherin expression was positive in 94% (16/17) of Snail positive cases and 86% (25/29) of Snail negative cases, indicating the absence of a statistically significant association. Results are summarized in **Table 1, Figure 1**.

E-cadherin expression does not correlate with BRAF status and established histopathologic prognosticators in papillary thyroid carcinoma

Overall, E-cadherin expression, based off of cumulative score (proportion of cells stained and intensity), yielded positivity in all cases. Due to this, we used the intensity score alone

BRAF and epithelial-mesenchymal transition in papillary thyroid carcinoma

Table 4. Studies evaluating the BRAF/Snail/E-cadherin pathway in papillary thyroid carcinoma

Study	Samples	BRAF	SNAIL	E-cadherin	Conclusions
<i>Walgenbach et al. (1998)</i> [21]	Papillary thyroid carcinoma biopsies (n=78)	BRAF not studied	Snail not studied	IHC	Decreased e-cadherin expression correlated with locoregional tumor recurrence, lymph node metastasis, distant metastasis, and shorter survival
<i>Hardy et al. (2007)</i> [17]	Thyroid carcinoma cell lines and papillary thyroid carcinoma biopsies (n=32)	BRAF not studied	RT-PCR, Western blotting, and IHC	RT-PCR	1. SNAIL is upregulated and e-cadherin downregulation in thyroid carcinoma cell lines 2. SNAIL expression enhances papillary thyroid carcinoma development in mice 3. SNAIL protein is expressed in patient samples
<i>Erdem et al. (2011)</i> [42]	Papillary thyroid carcinoma biopsies (n=79)	BRAF not studied	Snail not studied	IHC	Decreased e-cadherin expression is correlated with gender
<i>Guerra et al. (2012)</i> [43]	Papillary thyroid carcinoma biopsies (n=168)	DNA sequencing	Snail not studied	E-cadherin not studied	BRAF mutation correlated with age, tumor volume, and disease recurrence
<i>Liu et al. (2012)</i> [22]	Papillary thyroid carcinoma biopsies (n=81)	BRAF not studied	Snail not studied	IHC	Decreased e-cadherin expression correlated with increased age, invasion, lymph node metastasis and stage
<i>Baquero et al. (2013)</i> [18]	Thyroid cancer cell lines	Transfection with BRAFV600E DNA	Western blot	RT-PCR	1. BRAF mutation induces SNAIL upregulation via ERK1/2 dependent mechanism 2. SNAIL downregulated E-cadherin 3. This pathway promotes thyroid cancer cell migration and invasion
<i>Jung et al. (2015)</i> [23]	Papillary thyroid carcinoma (n=60) and anaplastic thyroid carcinoma (n=17) biopsies	BRAF not studied	IHC	IHC	1. E-cadherin expression was retained in all papillary thyroid carcinomas 2. Snail expression was more common in anaplastic thyroid carcinoma than papillary thyroid carcinoma 3. Epithelial-mesenchymal transition and cancer stem cell markers associated with more aggressive forms of thyroid carcinoma
<i>Mitchell et al. 2016 (current study)</i>	Papillary thyroid carcinoma biopsies (n=50)	Direct DNA sequencing	IHC	IHC	1. The interaction between BRAF and epithelial-mesenchymal transition in papillary thyroid carcinoma is not through induction of the Snail/E-cadherin pathway 2. BRAF may be of utility as putative therapeutic target in papillary thyroid carcinoma

BRAF and epithelial-mesenchymal transition in papillary thyroid carcinoma

to further stratify cases. Using this approach, 89% (41/46) of cases demonstrated positive E-cadherin expression; 84% (21/25) of BRAF mutant and 95% (20/21) of BRAFWT cases. E-cadherin expression did not correlate with established histopathologic prognosticators of poor clinical outcome. Results are summarized in **Table 2**.

BRAF mutation is associated with multiple established histopathologic prognosticators of poor clinical outcome

Statistically significant differences between BRAF mutant and BRAFWT samples were noted in the following: conventional (68% vs. 5%, 17/25 vs. 1/21) and tall cell (24% vs. 0%, 6/25 vs. 0/21) variants, extrathyroidal extension (32% vs. 5%, 8/25 vs. 1/21), infiltrative growth pattern (80% vs. 48%, 20/25 vs. 10/21), desmoplasia (72% vs. 29%, 18/25 vs. 6/21), psammoma bodies (48% vs. 10%, 12/25 vs. 2/21), and cystic change (32% vs. 5%, 8/25 vs. 1/21). Of note, compared to BRAF mutant samples, those that were BRAFWT were more commonly of the encapsulated follicular (4% vs. 52%, 1/25 vs. 11/21, $P < 0.001$) and microcarcinoma (0% vs. 29%, 0/25 vs. 6/21, $P = 0.007$) variants. Results are summarized in **Table 3**.

Discussion

In murine papillary thyroid carcinoma cells, it was demonstrated that downregulation of Snail resulted in upregulation of E-cadherin and inhibition of the malignant cell's capacity for migration and invasion [17]. Building on this, Baquero *et al.*, demonstrated that upregulation of Snail in thyroid carcinoma cells lines led to downregulation of E-cadherin expression [18]. We found E-cadherin to be expressed in almost all of our samples, irrespective of Snail expression, a finding at odds with most previously published observations (**Table 4**). This discordance may be attributed to differences in samples studied (i.e. cell lines vs. patient samples) and quantification methodology (i.e. PCR vs. immunohistochemistry). To better stratify our scoring, we then looked at intensity of E-cadherin expression alone; however almost 90% of our samples still retained E-cadherin expression. Taken together, our findings argue that epithelial-mesenchymal transition in papillary thyroid carcinoma is not regulated via loss of E-cadherin expression. Further in support of this, over 94%

of samples expressing Snail also demonstrated expression of E-cadherin. These findings argue that progression of papillary thyroid carcinoma, a variant with a less aggressive phenotype, is not mediated by upregulation of the transcriptional repressor Snail with a concomitant decrease of its target E-cadherin. Given the role of these molecules in poorly differentiated variants of thyroid carcinoma, it is possible that other molecules in the tumor microenvironment may contribute to the *in vitro* observations of the enhanced role of Snail in E-cadherin in epithelial-mesenchymal transition. Further in support of this, a recent study by Ma *et al.* demonstrates that dedifferentiation, in the form of enhanced expression of stem cell genes (i.e. Oct4, Rex1, CD15, and Sox2), associates with epithelial-mesenchymal transition progression in thyroid carcinoma cell lines [19]. Specifically, *in vitro* analysis of papillary thyroid carcinoma cell lines revealed decreased expression of the epithelial marker E-cadherin and increased expression of epithelial-mesenchymal transition regulators including Snail, Slug, TGF- β 1/3, and the mesenchymal marker vimentin, with concordant acquisition of a cancer stem cell-like phenotype [19]. Further studies evaluating cancer stem cells in papillary thyroid carcinoma samples may help in clarifying the relationship between tumor microenvironment and epithelial-mesenchymal transition.

In 2011, Liu *et al.* noted a dichotomy in E-cadherin expression at the tumor front as compared with the tumor focus [20]. In the same study it was noted that loss of E-cadherin expression at the invasive front of papillary thyroid carcinoma correlated with the development of lymph node metastasis [20]. We also noted that a loss of E-cadherin expression confined to the invasive tumor front ($n=10$). In addition, we noted that these areas of E-cadherin repression at the invasive front retained expression of Snail.

The utility of E-cadherin expression as a prognosticator of clinical outcome in papillary thyroid carcinoma is uncertain. Two previous studies correlated loss of E-cadherin with metastasis and shorter survival [21, 22]. However, more recent studies, our own as well as that of Jung *et al.*, demonstrating ubiquitous expression of E-cadherin in papillary thyroid carcinoma

BRAF and epithelial-mesenchymal transition in papillary thyroid carcinoma

ma argue against the prognostic utility of E-cadherin [23]. Potential causes of this discordance may be attributable to differences in methodology including dilution (1:100 vs. 1:50), temperature for primary antibody incubation (48°C vs. 4°C) as well as differences in the epitopes targeted by the primary antibody. In regards to Snail, while expression also did not appear to be of utility as a prognosticator in our cohort, a trend was noted between Snail expression and tumors <5 cm. The precise significance of this is unclear. Additional studies such as corroboration of this in a larger sample size is indicated.

Several studies have demonstrated the role of BRAF mutant in the progression and metastasis of select variants of thyroid carcinoma [18, 24-30]. A 2005 study demonstrated that oncogenic BRAF alters the expression of select genes associated with cell adhesion (i.e. *RUNX2*, MMPs), migration (i.e. chemokines) and proliferation (i.e. *Akt*) in cell lines derived from normal rat follicular cells *in vitro* [24]. Follow-up studies showed that *BRAFV600E* regulates the expression of matrix metalloproteinases (MMPs)-required for metastatic invasion-through an NFκB-dependent pathway in normal rat and human follicular cells *in vitro* as well as in patient samples [25-27]. Other molecules that have been associated with BRAF mutation and epithelial-mesenchymal transition in papillary thyroid carcinoma are the molecules Smad, thrombospondin-1, and TGFβ [28-30]. In 2013, Baquero *et al.* demonstrated that thyroid cancer cells expressing mutant BRAF showed upregulated Snail expression and downregulation of E-cadherin *in vitro* [18]. Furthermore, *in vitro* administration of a BRAF inhibitor resulted in a loss of migratory and invasive potential, arguing that this pathway was relevant in the epithelial to mesenchymal transition observed during the progression of select thyroid carcinomas [18]. Interestingly, the three cell lines used in this study were of follicular, undifferentiated, or anaplastic thyroid carcinoma lineage, rendering the role of BRAF mutation in the less aggressive, albeit more common, papillary thyroid carcinoma unstudied. Interestingly, our findings indicate that the Snail/E-cadherin pathway is not dysregulated by the presence of a BRAF mutation in papillary thyroid carcinoma. Considering that BRAF mutation is associated with poor prognosis in

papillary thyroid carcinoma, we hypothesize that the oncogenic protein may be influencing tumorigenesis through an alternative pathway, or may require additional “hits” to the tumor microenvironment prior to alterations in the Snail/E-cadherin cascade [11, 31]. This includes MAPK proteins downstream of BRAF (i.e. MEK/ERK), NFκB, the chemokine receptor CXCR4, all of which have been shown to influence Snail, and subsequently E-cadherin expression in non-thyroid malignancies [26, 32, 33].

Our findings, like those from previous studies, are in support of the utility of BRAF status as a prognosticator of patient outcome [3-11]. In our cohort, we found that the mutant BRAF genotype was associated with the tall cell histopathologic variant, presence of extrathyroidal extension, infiltrative growth pattern, desmoplasia, and psammoma bodies, all of which have been shown to be associated with a more aggressive tumor phenotype [34-37]. These findings support the utility of BRAF inhibitors, such as Vemurafenib, in the treatment of papillary thyroid carcinoma [38-40]. We also found that cystic change was also associated with BRAF mutation, although the prognostic utility of this feature is not fully established [41].

In conclusion, our findings indicate that the BRAF mutation does not appear to induce epithelial to mesenchymal transformation in papillary thyroid carcinoma via the Snail/E-cadherin pathway. Snail and E-cadherin expression do not appear to be of utility, as prognosticator of poor clinical outcome. The association between BRAF and poor prognosticators further supports the utility of BRAF as a putative therapeutic target in papillary thyroid carcinoma.

Acknowledgements

Findings in part presented as a poster at the 15th International Thyroid Congress and 85th Annual Meeting of the American Thyroid Association on October 21-22, 2015 at Lake Buena Vista, Florida.

Disclosure of conflict of interest

None.

Address correspondence to: Dr. Jagdish Dhingra, ENT Specialists, Inc., 825 Washington St # 310,

BRAF and epithelial-mesenchymal transition in papillary thyroid carcinoma

Norwood, MA 02062, UK. Tel: (857) 203-5992; Fax: (857) 203-5623; E-mail: jagdhingra@gmail.com

References

- [1] Davies L, Welch H. Current thyroid cancer trends in the United States. *JAMA Otolaryngol Neck Surg* 2014; 140: 317-22.
- [2] Enewold L, Zhu K, Ron E, Marrogi AJ, Stojadinovic A, Peoples GE, Devesa SS. Rising Thyroid Cancer Incidence in the United States by Demographic and Tumor Characteristics, 1980-2005. *Cancer Epidemiol Biomarkers Prev* 2009; 18: 784-91.
- [3] Nikiforova MN, Kimura ET, Gandhi M, Biddinger PW, Knauf JA, Basolo F, Zhu Z, Giannini R, Salvatore G, Fusco A, Santoro M, Fagin JA, Nikiforov YE. BRAF Mutations in Thyroid Tumors Are Restricted to Papillary Carcinomas and Anaplastic or Poorly Differentiated Carcinomas Arising from Papillary Carcinomas. *J Clin Endocrinol Metab* 2003; 88: 5399-404.
- [4] Kim KH, Kang DW, Kim SH, Seong IO, Kang DY. Mutations of the BRAF Gene in Papillary Thyroid Carcinoma in a Korean Population. *Yonsei Med J* 2004; 45: 818-21.
- [5] Xing M, Westra WH, Tufano RP, Cohen Y, Rosenbaum E, Rhoden KJ, Carson KA, Vasko V, Larin A, Tallini G, Tolaney S, Holt EH, Hui P, Umbricht CB, Basaria S, Ewertz M, Tufano AP, Califano JA, Ringel MD, Zeiger MA, Sidransky D, Ladenson PW. BRAF Mutation Predicts a Poorer Clinical Prognosis for Papillary Thyroid Cancer. *J Clin Endocrinol Metab* 2005; 90: 6373-9.
- [6] Lee JH, Lee ES, Kim YS. Clinicopathologic significance of BRAF V600E mutation in papillary carcinomas of the thyroid. *Cancer* 2007; 110: 38-6.
- [7] Oler G, Cerutti JM. High prevalence of BRAF mutation in a Brazilian cohort of patients with sporadic papillary thyroid carcinomas. *Cancer* 2009; 115: 972-80.
- [8] Kim TH, Park YJ, Lim JA, Ahn HY, Lee EK, Lee YJ, Kim KW, Hahn SK, Youn YK, Kim KH, Cho BY, Park DJ. The association of the BRAFV600E mutation with prognostic factors and poor clinical outcome in papillary thyroid cancer. *Cancer* 2012; 118: 1764-73.
- [9] Yan K, Lin X, Li S, Bao H, Zhao L, Liu X. Association of BRAF (V) 600E mutation with clinical pathological features in papillary thyroid carcinoma: meta-analysis. *Chinese J Clin Otorhinolaryngol Head Neck Surg* 2014; 49: 759-64.
- [10] Xing M, Alzahrani AS, Carson KA, Shong YK, Kim TY, Viola D, Elisei R, Bendlová B, Yip L, Mian C, Vianello F, Tuttle RM, Robenshtok E, Fagin JA, Puxeddu E, Fugazzola L, Czarniecka A, Jarzab B, O'Neill CJ, Sywak MS, Lam AK, Riesco-Eizaguirre G, Santisteban P, Nakayama H, Clifton-Bligh R, Tallini G, Holt EH, Sýkorová V. Association Between BRAF V600E Mutation and Recurrence of Papillary Thyroid Cancer. *J Clin Oncol* 2015; 33: 42-50.
- [11] Li F, Chen G, Sheng C, Gusdon AM, Huang Y, Lv Z, Xu H, Xing M, Qu S. BRAFV600E mutation in papillary thyroid microcarcinoma: a meta-analysis. *Endocr Relat Cancer* 2015; 22: 159-68.
- [12] Grabellus F, Worm K, Schmid KW, Sheu SY. The BRAF V600E Mutation in Papillary Thyroid Carcinoma Is Associated with Glucose Transporter 1 Overexpression. *Thyroid* 2012; 22: 377-82.
- [13] Lamouille S, Xu J, Derynck R. Molecular mechanisms of epithelial-mesenchymal transition. *Nat Rev Mol Cell Biol* 2014; 15: 178-96.
- [14] Carver EA, Jiang R, Lan Y, Oram KF, Gridley T. The Mouse Snail Gene Encodes a Key Regulator of the Epithelial-Mesenchymal Transition. *Mol Cell Biol* 2001; 21: 8184-8.
- [15] Wu Y, Zhou BP. TNF- α /NF- κ B/Snail pathway in cancer cell migration and invasion. *Br J Cancer* 2010; 102: 639-44.
- [16] Villarejo A, Cortes-Cabrera A, Molina-Ortiz P, Portillo F, Cano A. Differential Role of Snail1 and Snail2 Zinc Fingers in E-cadherin Repression and Epithelial to Mesenchymal Transition. *J Biol Chem* 2014; 289: 930-41.
- [17] Hardy RG, Vicente-Dueñas C, González-Herero I, Anderson C, Flores T, Hughes S, Tselepis C, Ross JA, Sánchez-García I. Snail Family Transcription Factors Are Implicated in Thyroid Carcinogenesis. *Am J Pathol* 2007; 171: 1037-46.
- [18] Baquero P, Sánchez-Hernández I, Jiménez-Mora E, Orgaz JL, Jiménez B, Chiloeches A. V600EBRAF promotes invasiveness of thyroid cancer cells by decreasing E-cadherin expression through a Snail-dependent mechanism. *Cancer Lett* 2013; 335: 232-41.
- [19] Ma R, Bonfond S, Morshed SA, Latif R, Davies TF. Stemness is derived from thyroid cancer cells. *Thyroid Endocrinol* 2014; 5: 114.
- [20] Liu Z, Kakudo K, Bai Y, Li Y, Ozaki T, Miyauchi A, Taniguchi E, Mori I. Loss of cellular polarity/cohesiveness in the invasive front of papillary thyroid carcinoma, a novel predictor for lymph node metastasis; possible morphological indicator of epithelial mesenchymal transition. *J Clin Pathol* 2011; 64: 325-29.
- [21] Walgenbach S, Sternheim E, Bittinger F, Görges R, Andreas J, Junginger T. Prognostic value of e-cadherin in papillary thyroid carcinoma. *Chirurg* 1998; 69: 186-190.
- [22] Liu C, Chen X, Gao Z, Liu Z, Tao X. The study of the correlation of papillary thyroid carcinoma's invasion toward Ezrin and E-cadherin. *Chinese J Clin Otorhinolaryngol Head Neck Surg* 2012; 26: 789-91.
- [23] Jung CW, Han KH, Seol H, Park S, Koh JS, Lee SS, Kim MJ, Choi IJ, Myung JK. Expression of cancer stem cell markers and epithelial-mesenchymal transition-related factors in anaplas-

BRAF and epithelial-mesenchymal transition in papillary thyroid carcinoma

- tic thyroid carcinoma. *Int J Clin Exp Pathol* 2015; 8: 560-68.
- [24] Melillo RM, Castellone MD, Guarino V, De Falco V, Cirafici AM, Salvatore G, Caiazzo F, Basolo F, Giannini R, Kruhoffer M, Orntoft T, Fusco A, Santoro M. The RET/PTC-RAS-BRAF linear signaling cascade mediates the motile and mitogenic phenotype of thyroid cancer cells. *J Clin Invest* 2005; 115: 1068-81.
- [25] Mesa C Jr, Mirza M, Mitsutake N, Sartor M, Medvedovic M, Tomlinson C, Knauf JA, Weber GF, Fagin JA. Conditional Activation of RET/PTC3 and BRAFV600E in Thyroid Cells Is Associated with Gene Expression Profiles that Predict a Preferential Role of BRAF in Extracellular Matrix Remodeling. *Cancer Res* 2006; 66: 6521-9.
- [26] Palona I, Namba H, Mitsutake N, Starenki D, Podtcheko A, Sedliarou I, Ohtsuru A, Saenko V, Nagayama Y, Umezawa K, Yamashita S. BRAFV600E Promotes Invasiveness of Thyroid Cancer Cells through Nuclear Factor κ B Activation. *Endocrinology* 2006; 147: 5699-07.
- [27] Frasca F, Nucera C, Pellegriti G, Gangemi P, Attard M, Stella M, Loda M, Vella V, Giordano C, Trimarchi F, Mazzone E, Belfiore A, Vigneri R. BRAF(V600E) mutation and the biology of papillary thyroid cancer. *Endocr Relat Cancer* 2008; 15: 191-205.
- [28] Riesco-Eizaguirre G, Rodríguez I, De la Vieja A, Costamagna E, Carrasco N, Nistal M, Santisteban P. The BRAFV600E Oncogene Induces Transforming Growth Factor β Secretion Leading to Sodium Iodide Symporter Repression and Increased Malignancy in Thyroid Cancer. *Cancer Res* 2009; 69: 8317-25.
- [29] Nucera C, Porrello A, Antonello ZA, Mekel M, Nehs MA, Giordano TJ, Gerald D, Benjamin LE, Priolo C, Puxeddu E, Finn S, Jarzab B, Hodin RA, Pontecorvi A, Nose V, Lawler J, Parangi S. B-RafV600E and thrombospondin-1 promote thyroid cancer progression. *Proc Natl Acad Sci U S A* 2010; 107: 10649-54.
- [30] Knauf JA, Sartor MA, Medvedovic M, Lundsmith E, Ryder M, Salzano M, Nikiforov YE, Giordano TJ, Ghossein RA, Fagin JA. Progression of BRAF-induced thyroid cancer is associated with epithelial-mesenchymal transition requiring concomitant MAP kinase and TGF β signaling. *Oncogene* 2011; 30: 3153-62.
- [31] Hong AR, Lim JA, Kim TH, Choi HS, Yoo WS, Min HS, Won JK, Lee KE, Jung KC, Park DJ, Park YJ. The Frequency and Clinical Implications of the BRAFV600E Mutation in Papillary Thyroid Cancer Patients in Korea Over the Past Two Decades. *Endocrinol Metab* 2013; 29: 505-13.
- [32] Zhu Y, Yang P, Wang Q, Hu J, Xue J, Li G, Zhang G, Li X, Li W, Zhou C, Zhao M, Wang D. The Effect of CXCR4 Silencing on Epithelial-Mesenchymal Transition Related Genes in Glioma U87 Cells. *Anat Rec (Hoboken)* 2013; 296: 1850-6.
- [33] Strippoli R, Loureiro J, Moreno V, Benedicto I, Lozano ML, Barreiro O, Pellinen T, Minguet S, Foronda M, Osteso MT, Calvo E, Vázquez J, Cabrera ML, Del Pozo MA. Caveolin-1 deficiency induces a MEK-ERK1/2-Snail-1-dependent epithelial-mesenchymal transition and fibrosis during peritoneal dialysis. *EMBO Mol Med* 2015; 7: 102-23.
- [34] Parikh HK, Rao RS, Shrikhande SS, Havaladar R, Deshmane VH, Parikh DM. Prognosticators of survival in differentiated thyroid carcinoma. *Indian J Otolaryngol Head Neck Surg* 2001; 53: 6-10.
- [35] Koperek O, Asari R, Niederle B, Kaserer K. Desmoplastic stromal reaction in papillary thyroid microcarcinoma. *Histopathology* 2011; 58: 919-24.
- [36] Ganly I, Ibrahimasic T, Rivera M, Nixon I, Palmer F, Patel SG, Tuttle RM, Shah JP, Ghossein R. Prognostic Implications of Papillary Thyroid Carcinoma with Tall-Cell Features. *Thyroid* 2013; 24: 662-70.
- [37] Pyo JS, Kang G, Kim DH, Park C, Kim JH, Sohn JH. The prognostic relevance of psammoma bodies and ultrasonographic intratumoral calcifications in papillary thyroid carcinoma. *World J Surg* 2013; 37: 2330-5.
- [38] Kim KB, Cabanillas ME, Lazar AJ, Williams MD, Sanders DL, Ilagan JL, Nolop K, Lee RJ, Sherman SI. Clinical Responses to Vemurafenib in Patients with Metastatic Papillary Thyroid Cancer Harboring BRAFV600E Mutation. *Thyroid* 2013; 23: 1277-83.
- [39] Ali SM, He J, Carson W, Stephens PJ, Fiorillo J, Lipson D, Palmer GA, Ross JS, Miller VA, Sherman J. Extended Antitumor Response of a BRAFV600E Papillary Thyroid Carcinoma to Vemurafenib. *Case Report Oncol* 2014; 7: 343-8.
- [40] Dadu R, Shah K, Busaidy NL, Waguespack SG, Habra MA, Ying AK, Hu MI, Bassett R, Jimenez C, Sherman SI, Cabanillas ME. Efficacy and Tolerability of Vemurafenib in Patients with BRAFV600E-Positive Papillary Thyroid Cancer: M.D. Anderson Cancer Center Off Label Experience. *J Clin Endocrinol Metab* 2015; 100: E77-E81.
- [41] Kim JY, Kim EK, Lee HS, Kwak JY. Conventional papillary thyroid carcinoma: effects of cystic changes visible on ultrasonography on disease prognosis. *Ultrasonography* 2014; 33: 291-97.
- [42] Erdem H, Gündođdu C, Şipal S. Correlation of E-cadherin, VEGF, COX-2 expression to prognostic parameters in papillary thyroid carcinoma. *Exp Mol Pathol* 2011; 90: 312-7.
- [43] Guerra A, Fugazzola L, Marotta V, Cirillo M, Rossi S, Cirello V, Forno I, Moccia T, Budillon A, Vitale M. A High Percentage of BRAFV600E Alleles in Papillary Thyroid Carcinoma Predicts a Poorer Outcome. *J Clin Endocrinol Metab* 2012; 97: 2333-40.